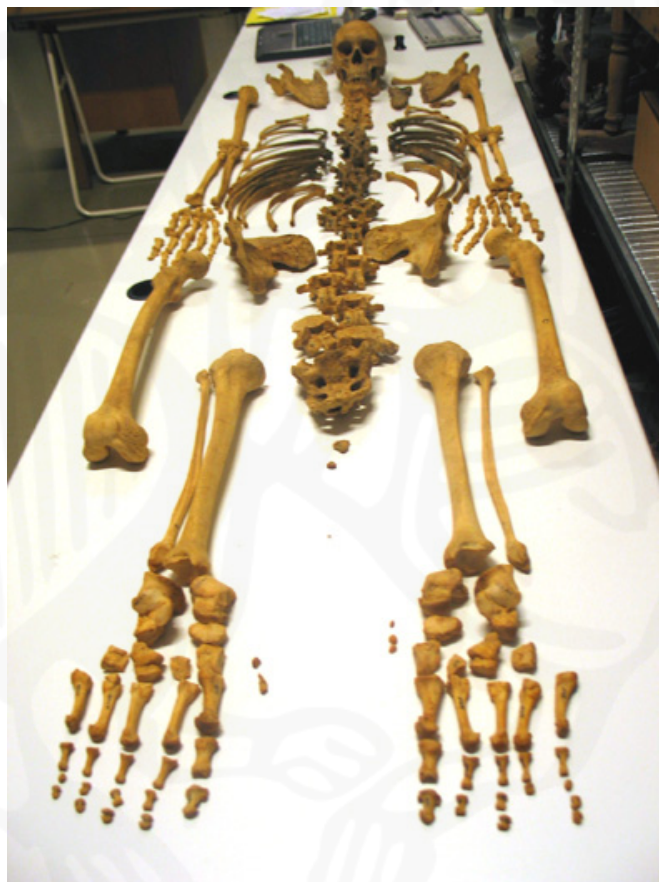

The Palaeopathology of Iceland: Preliminary report 2003.

Haffjarðarey, Neðranes & Viðey

Hildur Gestsdóttir



**Fornleifastofnun Íslands
FS225-99192
Reykjavík 2004**



The photograph on the cover is of skeleton HFE-A-011

© *Fornleifastofnun Íslands*
Bárugötu 3
101 Reykjavík

Sími: 551 1033
Fax: 551 1047
Netfang: fsi@instarch.is

TABLE OF CONTENTS

1	Introduction.....	4
2	Methods	4
2.1	Database	4
2.2	Preservation.....	5
2.3	Ageing.....	6
2.4	Sexing	7
2.5	Stature	7
2.6	Palaeopathology	7
3	Results	9
4	Haffjarðarey, Haffjörður (HFE).....	9
4.1	The material.....	10
4.1.2	Preservation	10
4.1.3	Age	10
4.1.4	Sex.....	11
4.1.5	Stature	11
4.2	Palaeopathology	12
4.2.1	Nutritional disease	12
4.2.2	Infectious disease.....	12
4.2.3	Trauma	14
4.2.4	Joint disease.....	17
4.2.4.1	Spinal joint disease.....	17
4.2.4.2	Other joint disease.....	19
4.2.5	Occupational stress indicators	21
4.2.6	Neoplastic disease	22
4.2.7	Congenital disease	23
4.2.8	Non-specific stress indicators.....	24
4.2.9	Dental disease	25
4.2.10	Other.....	27
5	Neðranes, Stafholtstungum (NNS).....	28
5.1	The material.....	28
5.1.1	Preservation	29
5.1.2	Age	29
5.1.3	Sex.....	29
5.1.4	Stature	30
5.2	Palaeopathology	30
5.2.1	Infectious disease.....	30
5.2.2	Trauma	30
5.2.3	Joint disease.....	30
5.2.3.1	Spinal joint disease.....	30
5.2.3.2	Other joint disease.....	31
5.2.4	Non-specific stress indicators.....	31

5.2.5 Dental disease	31
6 Viðey, Kollafirði (VEY)	32
6.1 The material.....	32
6.1.1 Preservation	32
6.1.2 Age	33
6.1.3 Sex.....	33
6.1.4 Stature	34
6.2 Palaeopathology	34
6.2.1 Nutritional disease	34
6.2.2 Infectious disease	34
6.2.3 Trauma	37
6.2.4 Joint disease.....	40
6.2.4.1 Spinal joint disease.....	40
6.2.4.2 Other joint disease.....	41
6.2.5 Occupational stress indicators	42
6.2.6 Neoplastic disease	43
6.2.7 Congenital disease	43
6.2.8 Metabolic and endocrine disease	43
6.2.9 Non-specific stress indicators.....	44
6.2.10 Dental disease	44
6.2.11 Other.....	47
7 Conclusion	47
References.....	49
Appendix A – Haffjarðarey	51
Appendix B – HFE-A-014c	53
Appendix C - Neðranes	54
Appendix D – Viðey.....	55

1 INTRODUCTION

This report contains the summary of the palaeopathological analysis carried out for the project *The Palaeopathology of Iceland (Heilsufarssaga íslendinga frá landnámi til 18. aldar)* in 2003. The aim of this project is to carry out a complete palaeopathological study of skeletons dating from the 9th century (Settlement period) until the 18th century excavated in Iceland, to increase the understanding of the health of Icelanders in the past and lay the foundations for further research in this field. For this purpose the age and sex of each individual will be diagnosed and their stature calculated. All palaeopathological changes on every skeleton will be recorded and these will be used to diagnose, where possible, specific diseases. An initial emphasis will be placed on nutritional disease, infectious disease, trauma, changes associated with activity related stress and dental disease (carious lesions, abscesses and periodontal disease), as these are the factors which give the clearest view of general health within a population (Roberts and Manchester, 1995; Ortner and Putschar, 1981). The results from these studies will then be used to carry out a palaeodemographic study to increase our understanding of the health of Icelanders in the past and changes therein.

The first year of the project has analysed a total of 101 skeletons from three sites, held in both the National Museum of Iceland and Árbæjarsafn – Reykjavík Museum. The project is funded by the Icelandic Research Council (Rannsóknarráð Íslands), and thanks are also due to the Lilja Árnadóttir and Halldóra Ásgeirsdóttir (National Museum of Iceland) and Anna Lísu Guðmundsdóttir (Árbæjarsafn – Reykjavík Museum) for allowing access to the material and providing a workspace, and to Dr. Guðmundur Eyjólfsson and Anna Birna Ólafsdóttir (Læknasetrið Mjódd) for carrying out and assisting in the analysis of some preliminary X-rays.

2 METHODS

2.1 DATABASE

An Access database was designed to facilitate the recording for this project. This database holds accurate records of each age and sexually diagnostic characteristic, measurements to calculate stature, and summaries of the results of these analyses (for

information about the standards used see sections 2.3 – 2.5). Dental recordings, with development anomalies and pathological changes are also held, as well as detailed recordings of all individual pathological changes on each bone. The information entered into the database conforms to standard osteological terms that allows for consistent recording methods, as well as allowing consistent analytical approaches to the recorded information. The database is currently designed only to accept information, and a user-friendly interface has still to be designed. The design of the database is such that it can be integrated both with the archaeological field survey database (Ísleif) developed by the Institute of Archaeology, and the National Museum of Iceland skeletal database.

2.2 PRESERVATION

The recording of the preservation of each skeleton was carried out in three stages. Firstly, preservation was recorded visually on a skeletal recording sheet, with the bones missing coloured in black (see figure 1). Secondly, each skeleton was graded, from 1-5 (see table 1), depending not only on the amount of material present, but also its viability for palaeopathological study. For example, in some cases most the skeletal elements are present, but if the preservation of each bone is poor, then that reduces the amount

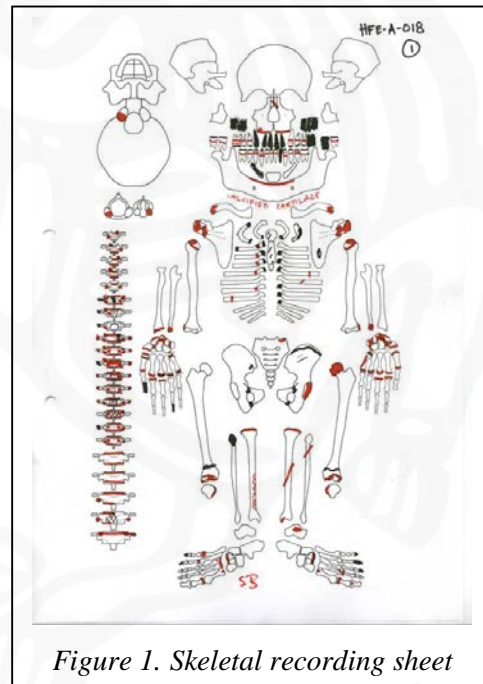


Figure 1. Skeletal recording sheet

Grade	Preservation
1	>90%
2	75-90%
3	50-75%
4	30-50%
5	<30%

Table 1. Preservation

of macroscopic analysis that can be carried out. Thirdly, a count sheet was kept to record the number of individual bones and joints preserved in each collection, with a separate sheet for adults and juveniles.

2.3 AGEING

Osteologically, skeletons under 18 years of age at the time of death are classed as juveniles, and those over 18 years, adults. The methods for determining the age at death of juvenile and adult skeletons differ. The methods used for juvenile skeletons mostly depend on the development of the skeleton and teeth. In this study as many of the following methods as preservation allowed were used:

1. The development of the dentition (Ubelaker, 1989).
2. The state of fusion of the secondary ossification centres and epiphyses of long bones (see for example Schwartz, 1995).
3. The comparison of measurements of the long bones to standards developed by Hoppa (1992).
4. In the Haffjarðarey collection there were several foetal or perinatal skeletons. These were aged by measurements of the long bones compared to standards by Scheur *et al.* (1980).

Age at death of adult skeletons was determined mainly by degenerative changes to joint surfaces. In this study as many of the following methods as preservation allowed were used:

1. The auricular surface ageing method devised by Lovejoy *et al.* (1985).
2. The Suchey-Brooks method of pubic symphysis ageing (Brooks & Suchey, 1990).
3. Cranial suture closure (Meindl & Lovejoy, 1985).

Age	Category
-36 wks	Foetal
36-40 wks	Perinatal
0-0.5	Younger neonate
0.5-1	Older neonate
1-4	Younger juvenile
4-8	Older juvenile
8-13	Younger subadult
13-18	Older subadult
18-25	Young adult
25-35	Younger middle adult
35-45	Older middle adult
45+	Mature adult

Table 2. Age categories

In addition the enamel wear on the mandibular molars was recorded to try and develop a dental wear ageing method suitable for Icelandic skeletons, as existing standards (e.g. Miles, 1963) do not work on Icelandic skeletal material. This is probably due to a lower consumption of grain in Iceland than in continental Europe, which means that there is less grit from the grinding process in their food. To facilitate statistical analysis, all the aged

skeletons were put into one of the categories presented in table 2.

2.4 SEXING

Juvenile skeletons are not suitable for sexing, as the sexually diagnostic characteristics have not fully developed. The sexing of the adult skeleton in this study was based, where preservation allowed, on sexually diagnostic characteristics of the cranium and pelvis (see for example Schwartz, 1995 and Buikstra & Ubelaker, 1994) and measurements of the width of several articular surfaces compared to standards presented by Bass (1995) and Brothwell (1981). In some instances the results of the sexing was inconclusive, in these instances the results are presented as “male?” or “female?”

2.5 STATURE

The calculations of the living stature of adult skeletons were based on measurements of complete long bones compared to standards devised by Trotter & Gleser (1958), and in those cases where the long bones were fragmented, on standards developed by Steele & McKern (1969). A comprehensive method for calculating the living stature of juvenile skeletons has not been developed, and so the stature of juveniles was not estimated.

2.6 PALAEOPATHOLOGY

Bones will continue to regenerate throughout an individual’s life, with constant build-up and breakdown of bone. Apart from direct trauma, all pathological conditions in bone are caused by disturbances in the functions of osteoblast cells, which control bone growth, and osteoclast cells, which control the breakdown of bone. The only difference is where and how this abnormal growth and/or destruction takes place; e.g. is the new bone smooth or porous? Is the change in the cortical- or trabecular bone or both? Is the pathology active or healed.

Bone changes are often secondary changes in a disease process, and pathological changes cannot always be associated with a specific disease. It is therefore important that the initial recording of pathological changes on a skeleton should be purely descriptive, and that each pathological change on each bone be accurately recorded using consistent and standard terms throughout recording (Ortner & Putschar, 1981). Within the palaeopathological database developed for this project, each pathological bone was described as accurately as possible using the criteria shown in table 3. Much of the terminology used, in particular in the bone formation and bone destruction keywords, is based on a draft document by Ortner (1996). In addition the location of each pathology was recorded visually on the skeletal recording sheet in red (see figure 1).

Column	Format	Description
ACC No	Text	Skeleton number as recorded in the National Museum Skeletal Database
Area	Drop-down list	Area of the skeleton, i.e. Cranium, axial, upper limb, lower limb
Bone	Drop-down list	Bone affected.
Side	Drop-down list	i.e. Right, left, N/A or unknown.
Abnormality keyword	Drop-down list	i.e. shape, size, abnormal bone formation, abnormal bone destruction, or combination of the two
Bone formation keyword	Drop-down list	i.e. what type of bone formation
Bone destruction keyword	Drop-down list	i.e. what type of bone destruction
Abnormality	Descriptive	Description of the pathological bone changes. An attempt is made to use as standardised language as possible.
Grade	Drop-down list	Grade of joint changes, 1. slight, 2. medium, 3. heavy.
Active/Healed	Drop-down list	Whether the lesion is active or healed, where applicable
Disease group	Drop-down list	List of disease categories, e.g. infectious, joint, trauma, neoplastic etc.
Disease	Descriptive	Further information on the disease, for example if a specific disease can be diagnosed, e.g. tuberculosis, multiple myeloma, etc.
Photo	Drop-down list	Whether a record photo was taken of the diseased bone.

Table 3. Palaeopathological recording.

3 RESULTS

The results for each site are presented separately. A summary of the preservation, ageing, sexing and measurements of stature for each individual skeleton is given in the appendices.

The results of the pathological analysis are presented as a summary of each disease group. When individual skeletons are discussed their estimated sex (for adults) and age is included in brackets. At the end of the discussion for each disease group a percentage summary of each disease in the section will be given. For the purpose of this preliminary report, these are calculated as a percentage of the population as a whole, with no account taken of the preservation of various elements, age or any other factors. This report represents the first stage of analysis, and in several cases further analysis is required, with X-rays, consultation with specialists and further consideration given to differential diagnosis.

4 HAFFJARÐAREY, HAFFJÖRÐUR (HFE)

It is not known when a church was first built in Haffjarðarey, but the earliest charters, dating to 1223, mention a church on the island. It is known that Bishop Gísli Jónsson abolished the church in 1563. It is therefore likely that the cemetery was in use for five centuries, from c.1200-1563 (Jón Steffensen, 1945). The island is severely eroded, and this erosion is documented back to 1714 (JÁM V). Vilhjálmur Stefánsson carried out the first excavations in the island in 1905. He recovered at least 50 skulls, most of which probably lay on the surface, and took these to the United States; they are currently held in the Peabody Museum of Archaeology and Ethnology, Harvard University. Jón Steffensen and Kristján Eldjárn excavated the skeletons preserved in the National Museum of Iceland in 1945. They excavated a total of 24 *in situ* skeletons and bones from an additional 34 individuals which had been disturbed, a total of 58 individuals. The amount of disturbance to the cemetery prior to the 1945 makes it difficult to determine what percentage of the original population of the cemetery this represents.

4.1 THE MATERIAL

For detailed information on the material, see appendices A and B.

4.1.2 PRESERVATION

There are 52 skeleton numbers in the Haffjarðarey collection, representing 54 individuals (HFE-A-014c represents commingled skeletons with an MNI (Minimum Number of Individuals) of 3). The preservation of the material in most instances is

Preservation	
>90%	8
75-90%	12
50-75%	17
30-75%	13
<30%	1

Table 4. HFE preservation

excellent. Most of the damage to the bone is caused by whitening or erosion due to exposure, and in several instances bones are missing, quite commonly the ribs, again probably due to exposure. The preservation of the material is shown in table 4. Of the 51 individual skeletons in the collection, 68.5% have 50% preservation or more.

4.1.3 AGE

The percentage of juvenile skeletons in the Haffjarðarey collection is unusually high. Of the 54 individuals represented, 59.3% are juveniles. It is not unusual in Icelandic

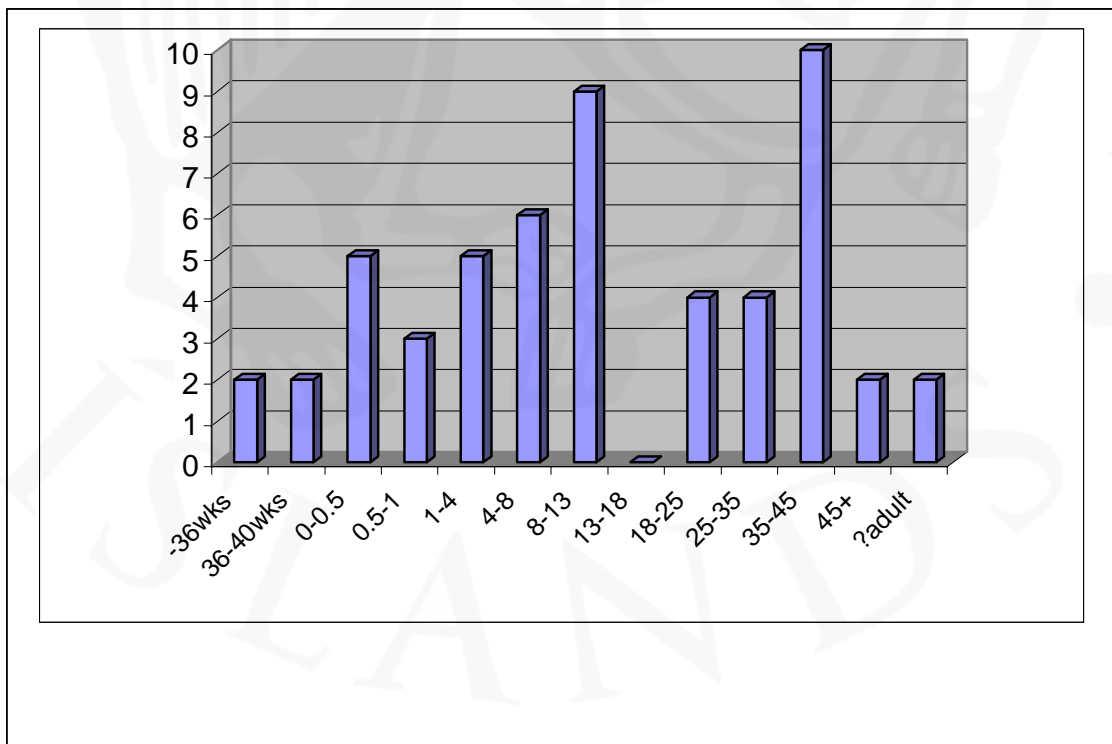


Figure 2. HFE age

medieval cemeteries to see a gender division, women to the north and men to the south, and in those instances the children are frequently allocated a part of the cemetery, frequently close to the church. The high percentage of juveniles in the Haffjarðarey collection preserved at the National Museum indicates that this was probably the case there, and that the 1945 excavation on the site mainly took place in the part of the cemetery allocated to children. The age division of the skeletons from Haffjarðarey is shown in figure 2.

4.1.4 SEX

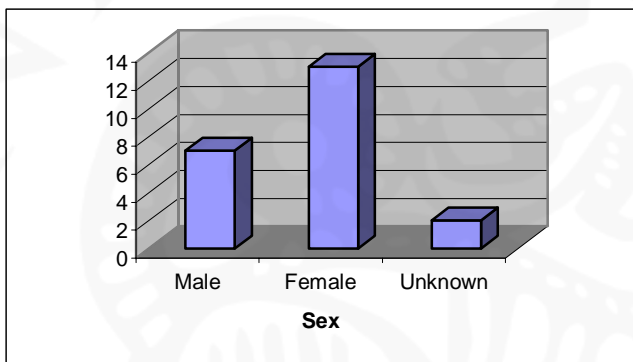


Figure 3. HFE sex

Of the 22 adult skeletons in the collection, only two could not be sexed. The high percentage of women (they represent 59.1% of the adult population) indicates that the 1945 excavation took place in the northern part of the cemetery.

4.1.5 STATURE

Of the adults in the population, 17 were preserved well enough to measure their stature. This included 11 females, 5 males and 1 adult of unknown sex. The results are represented in figure 4.

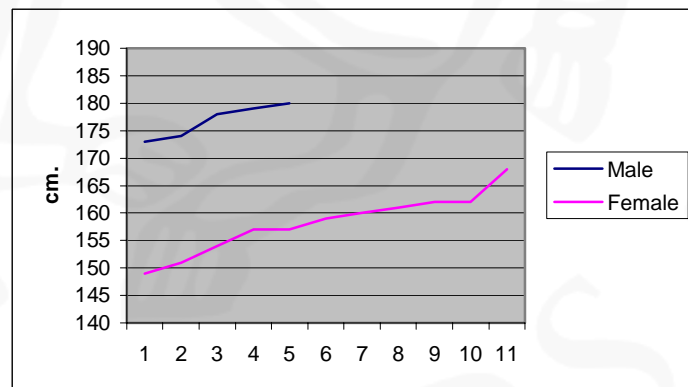


Figure 4. HFE stature

4.2 PALAEOPATHOLOGY

4.2.1 NUTRITIONAL DISEASE

Four individuals have changes indicative of nutritional disease. This is in all instances *cribra orbitalia*, porous lesions in the orbits; this is most commonly thought to be associated with iron deficiency anaemia (Roberts & Manchester, 1995). In three cases the *cribra orbitalia* is active, HFE-A-014b (0.5-1), HFE-A-017a (4-8) and HFE-A-026 (8-13), but in the fourth case it is healed, HFE-A-016 (female, 25-35).

- *Cribra orbitalia* 7.5%

4.2.2 INFECTIOUS DISEASE

Thirteen individuals in the Haffjarðarey collection have infectious changes involving bone. One skeleton, HFE-A-024 (female, 18-25), has a possible gumma on the frontal bone (see figure 5), a depression on the right side of the endocranial surface of the bone, overlying the frontal tuberosity. The depression is 17mm in diameter, and its base is uneven, with smaller pits inferior to it. No changes are seen ectocranially. This is possibly *caries sicca*, which is diagnostic of syphilis. There are however no further changes on the skeleton supporting such a diagnosis, so this must be put forward very tentatively, and merits further study.

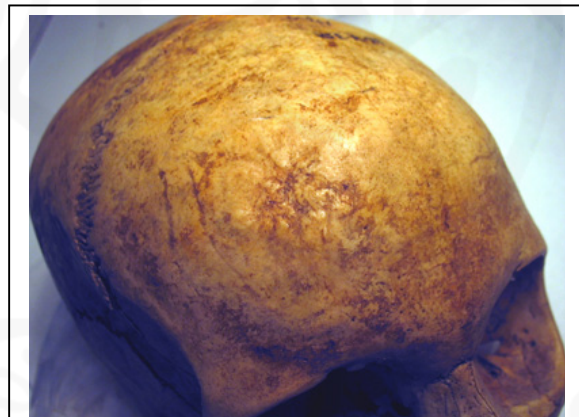


Figure 5. HFE-A-024. *Caries sicca*?

Non-specific infections in bone are usually seen as osteomyelitis involving abscess formation and enlargement of the affected bone due to new bone formation or periostitis, involving surface inflammation of the bone. These are caused either by the pathogenic bacteria being carried through the blood stream from the initial site of infection to the bone, most commonly the femur or tibia, or, less commonly by a bone penetrating injury (Roberts and Manchester, 1995). There are nine cases of

osteomyelitis in the Haffjarðarey skeletal collection, and nine cases of periostitis with bones other than the tibiae being involved (for cases just involving the tibiae, see discussion on occupational stress indicators, section 4.2.5). There are two cases of just the femora being involved, in both cases healed. These are HFE-A-016 (female, 25-35), right femur only and HFE-A-019 (male, 25-35), bilateral. There are four cases of both femora and tibiae being involved, HFE-A-006 (female, 18-25), where the left femur and tibia have healed periosteal bone formation; HFE-A-028 (8-13), with bilateral involvement and both active and healed bone formation; HFE-A-032 (female, 18-25) with the left femur and tibia being involved, as well as the right fibula and HFE-A-021b (8-13) with bilateral involvement, as well as periosteal bone formation on the outer surface of three 3rd-10th ribs. In this case there are also both active and healed new bone formation. One individual, HFE-A-027 (8-13), has active periosteal bone formation on the left humerus and right ulna. HFE-A-014c is a commingled collection representing at least three individuals. Within that group there is a right humerus and a right tibia with severe active periostitis (see figure 6). These both belong to an individual 0-0.5 years old, probably the same individual. One skeleton in the Haffjarðarey collection has widespread periostitis involving several long bones, indicating a severe infection. This is HFE-A-014i (8-13) who has active new bone formation on both humeri, the right ulna, both femora and tibiae and the right fibula.



HFE-A-019 (female, 25-35) has a possible parasitic infection. This is seen in the form of a calcified cyst, 13mm in diameter. No record exists of where in the body the cyst was located. A possible diagnosis for this would be *Echinococcosis*, or tapeworm. This is usually diagnosed palaeopathologically through the presence of mineralised outer shells hydatid cysts. The *Echinococcus* worm lives in the intestines of dogs and foxes, and the parasitic eggs are passed to humans through contamination of food or water by faeces. Historically Iceland had the highest incidence of *Echinococcosis* in Europe (Ortner & Putschar, 1981; Roberts & Manchester, 1995).

There are three further cases of non-specific infection. The styloid process of the both 3rd metacarpals of HFE-A-022 (male, 35-45) and the right of HFE-A-008 (female, 35-45) have been completely resorbed, in addition to there is possibly a small cloaca superior to the distal articular surface of the left radius of the latter. There is, however, no swelling of the bone, so it does not appear to be osteomyelitis. The third case is a small area of porous destruction distal to the right superior facet of the 1st cervical vertebra of HFE-A-019 (male, 25-35).

- *Syphilis(?) 1.9%*
- *Osteomyelitis(?) 1.9%*
- *Periostitis 16.7%*
- *Echinococcosis 1.9%*
- *Non-specific infectious disease 3.7%*

4.2.3 TRAUMA

Twelve individuals have fractures of one or more bone. Of these there are seven who have a fracture of only one bone. This includes two individuals with possible fractured clavicles, both healed, HFE-A-014f (female, 25-35), the right clavicle and HFE-A-014n (8-13), the left clavicle. Two individuals have fractured patellae, both healed. They are HFE-A-013 (female, 35-45), the left patella and HFE-A-014e (male, 35-45), the right (see also discussion on osteoarthritis, section 4.2.4). HFE-A-004 (adult of unknown age and sex) has a healed depressed fracture of the distal articular surface of the right tibia (see also discussion on osteoarthritis, section 4.2.4.2 and tibial periostitis, section 4.2.5). HFE-A-014h (female, 35-45) has a healed fracture of the right lower 1st proximal phalange and HFE-A-019 (male, 25-35) has a possible healed fracture of the right lower 2nd middle phalange.

Five individuals have multiple fractures. HFE-A-011 (male, 35-45) has a possible compression fracture of the 7th cervical vertebrae, a transverse fracture of the 7th right rib, a possible fracture of the left clavicle and a fracture of the left upper 2nd proximal phalange. This individual also has a lump, 18mm in diameter, superior to the temporal bone on the anterior part of the parietal. No new bone formation evident on the surface, and is possibly some sort of sub-cortical swelling, or perhaps caused by a blunt force trauma. Further analysis is required here. All these fractures are long standing, and may well be caused by the same traumatic event.

HFE-A-014g (female, 25-35) has a warped intermaxillary suture, possibly indicative of a nasal fracture. In addition the acromion of the right scapula has fractured with reunion of the fragment. Both these are long standing and possibly part of the same traumatic event.

HFE-A-018 (male, 35-45) has a fracture of the nasal bones, compression fracture of the 6th thoracic and 3rd lumbar vertebrae, complete fracture of the 9th right and 6th and 7th left ribs, without reunion of the fragments, a possible fracture of the right 5th metacarpal and a severe *contra coup* fracture of the left tibia and fibula (see figure 7). The tibia fracture is oblique on the middle third of the bone, extending from 79mm below the distal edge of the lateral condyle, to 155mm below the distal part of the medial condyle. The callus formation is lamellar bone, well organised and localised around the fracture line. Apposition, medial to lateral (measured from dry bone) 87,5%, there is little or no angulation. The fibula has an oblique fracture of the proximal third of the shaft. The fracture line is clear with very disorganised, spiculed lamellar bone sealing it. Apposition, anterior - posterior, is 27,2% (measured from dry bone), and malalignment is 19° (see also discussion on osteoarthritis, section 4.2.4.2). Although all these fractures show evidence of healing, they have not healed to an equal extent, so they are clearly not a part of the same traumatic event. The *contra coup* fracture and the nasal fracture for example have long standing lamellar bone formation (and may well have occurred at the same time), while the rib fractures have some porous woven bone formation, and the fragments have not reunited onto the shaft (although they might well have done given time), suggesting that they occurred shortly before death.



Figure 7. HFE-A-018. *Contra coup* fracture of the left tibia & fibula

HFE-A-020 (female, 35-45) has a healed compression fracture of the 5th lumbar vertebra and a complete fracture of the right upper 3rd middle phalange. The fragment has reunited with slight posterior displacement.

HFE-A-022 (male, 35-45) has a possible fracture across the inferior edge of the intermaxillary suture, between the two 1st incisors (see figure 8). On the buccal side the fracture line extends on the right bone, approximately 9mm long, on the lingual side it is seen on the left bone, 10mm long and 3mm wide, extending into the incisive fossa. The fracture line is long standing, well sealed with organised plaque lamellar bone, and the fracture line is hardly visible on the buccal side. There has been some warping of the teeth though, with a large gap between the two 1st incisors and the intermaxillary suture has warped, suggesting that the nose was also affected. The lack of damage to the teeth and the well-healed nature of the trauma suggest it occurred during childhood. There is also a possible fracture of the distal corner of the posterior calcaneal articular surface of the left talus.

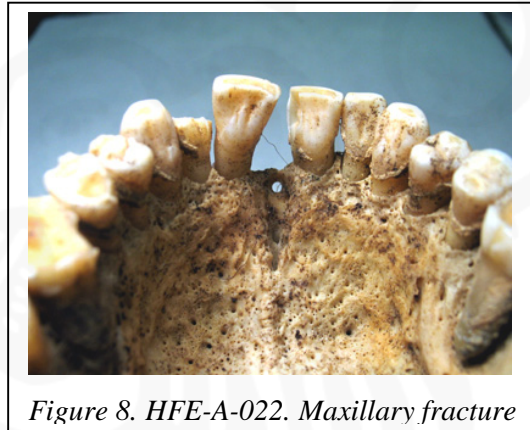


Figure 8. HFE-A-022. Maxillary fracture

Osteochondritis dissecans is caused by the death of bone tissue within a joint due to a significant obliteration of the blood supply to the bone because of some traumatic event. The necrotic fragment is then either loose within the joint, resorbed or can heal back (Roberts and Manchester, 1995). Three individuals in the Haffjarðarey collection are affected. HFE-A-006 (female, 18-25), has *osteochondritis dissecans* of the left scapula, the fragment has not rehealed; HFE-A-007 (female, 18-25), the proximal articular surface of the right lower 1st proximal phalange is affected and HFE-A-008 (female, 35-45), with the medial epicondyle of the left femur, with the fragment rehealed, the right 1st metatarsal and the left lower 1st proximal phalange being affected. In the latter two cases the proximal articular surface is affected and the fragments have not healed back.

Four individuals have calcified cricoid and/or thyroid cartilage. This is usually associated with strangulation or severe trauma to the neck. HFE-A-018 (male, 35-45), HFE-A-019 (male, 25-35) and HFE-A-022 (male, 35-45) have calcified thyroid cartilage only, while HFE-A-011 (male, 35-45) also has calcified cricoid cartilage.

There are three other changes that are possibly traumatic. There is almost complete resorption of distal end of the upper 1st distal phalange and one other unsided distal phalange of HFE-A-008 (female, 35-45). This is possibly caused by frostbite, although it would need further analysis to confirm that. HFE-A-020 (female, 35-45) has a bony outgrowth on one upper left middle phalange, possibly a soft tissue trauma, and HFE-A-032 (female, 18-25) has a dent in the side of the 1st thoracic vertebrae, between the costal facets.

- *Total fractures 22.2%*
 - **Cranial(?) 1.9%*
 - **Nasal 5.6%*
 - **Maxilla 1.9%*
 - **C vertebrae (compression) 1.9%*
 - **T vertebrae (compression) 1.9%*
 - **L vertebrae (compression) 3.7%*
 - **Rib 3.7%*
 - **Clavicle 5.6%*
 - **Scapula 1.9%*
 - **Hand/wrist 5.6%*
 - **Patella 3.7%*
 - **Tibia 3.7%*
 - **Fibula 1.9%*
 - **Foot/ankle 5.6%*
- *Osteochondritis dissecans 5.6%*
 - **Scapula 1.9%*
 - **Femur 1.9%*
 - **Metatarsal 3.7%*
 - **Lower phalanges 1.9%*
- *Strangulation / neck trauma 7.4%*
- *Frostbite(?) 1.9%*
- *Soft tissue damage(?) 1.9%*
- *Other trauma(?) 1.9%*

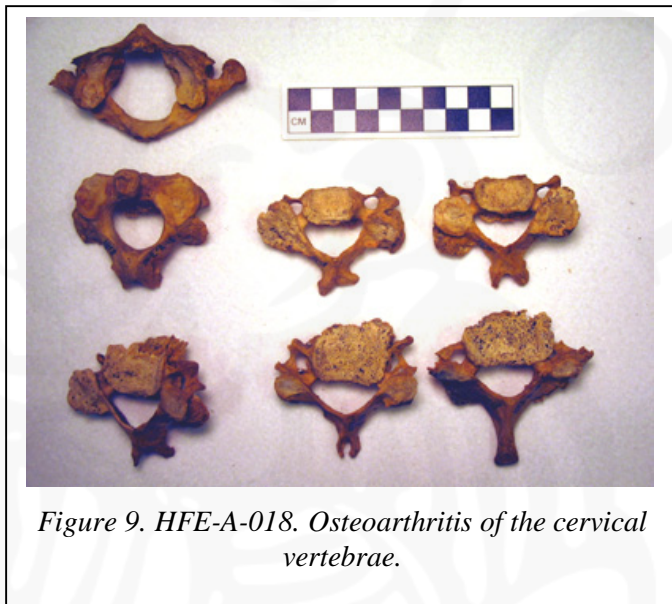
4.2.4 JOINT DISEASE

4.2.4.1 SPINAL JOINT DISEASE

Eleven individuals in the Haffjarðarey population have osteoarthritis of the spine. This is diagnosed when either there is eburnation of the joint surface, or two other severe joint changes, i.e. osteophytes, increased porosity or fusion. Two have osteoarthritis of the cervical and thoracic vertebrae; HFE-A-006 (female, 18-25) and HFE-A-022 (male, 35-45), and one individual has osteoarthritis of the cervical and lumbar vertebrae, HFE-A-014f (female, 25-35).

One individual, HFE-A-014e (male, 35-45) has osteoarthritis of just the thoracic vertebrae, while two, HFE-A-008 (female, 35-45) and HFE-A-016 (female, 25-35) have osteoarthritis of the thoracic and lumbar vertebrae. See also discussion on congenital disease for the latter, section 4.2.7.

One individual, HFE-A-013 (female, 35-45) has osteoarthritis of just the lumbar vertebrae. There are four skeletons that display osteoarthritic changes in the cervical, thoracic and lumbar vertebrae, HFE-A-011 (male, 35-45), HFE-A-015 (female, 45+), HFE-A-020 (female, 35-45) and HFE-A-018 (male, 35-45). For the last see also discussion on trauma, section 4.2.3 (see figure 9).



Schmorl's nodes are changes on the vertebral body surfaces, usually affecting the thoracic and lumbar vertebrae, associated with the degeneration of the intervertebral disks. Their specific aetiology is uncertain, but trauma is frequently implicated (Roberts & Manchester, 1995). Eleven individuals in the Haffjarðarey collection have Schmorl's nodes. In six cases just the thoracic vertebrae are affected; four females, HFE-A-014f, HFE-A-014g & HFE-A-016 (25-35) and HFE-A-015 (45+), and two males HFE-A-019 (25-35) and HFE-A-014e (35-54). In four cases both the thoracic and the lumbar vertebrae are affected; two females, HFE-A-007 (18-25) and HFE-A-008 (35-45), and two males, HFE-A-011 and HFE-A-022 (35-45). There is one case of just the lumbar vertebrae being affected, HFE-A-006 (female, 18-25)

In addition to these, degenerative joint changes, i.e. osteophyte formation and increased porosity, in the spinal column are common. In fact there are some degenerative spinal changes in all the adult skeletons that have preserved vertebrae.

In four cases a pseudoarthrosis has formed at the lower end of the spine, as a result of kyphosis. In one case this is between the 5th and the 6th vertebrae, HFE-A-016 (female, 25-35), see also discussion on congenital disease, section 4.2.7, but the other three cases are between the lowest lumbar vertebrae and the sacrum, HFE-A-011 (male, 35-45), HFE-A-018 (male, 35-45) and HFE-A-022 (male, 35-45). In the case of HFE-A-011 there pseudoarthrosis is between a supernumerary 6th lumbar vertebrae and the sacrum.

- *Osteoarthritis, C vertebrae* 13.0%
- *Osteoarthritis, T vertebrae* 16.7%
- *Osteoarthritis, L vertebrae* 14.8%
- *Schmorl's nodes, thoracic vertebrae* 18.5%
- *Schmorl's nodes, lumbar vertebrae* 9.3%
- *Lumbar pseudoarthrosis* 7.4%

4.2.4.2 OTHER JOINT DISEASE

As with the spinal joints, osteoarthritis in other joints was diagnosed where eburnation was present, or where two other severe features of degenerative joint disease, osteophyte formation, increased porosity or fusion, were recorded.

In the Haffjarðarey skeletal population there were a total of twelve individuals with osteoarthritis in joints other than the spinal joints. Of these, six had only one or two joints affected. HFE-A-020 (female, 35-45) had bilateral osteoarthritis of the shoulders (see also discussion on occupational stress indicators, section 4.2.5). HFE-A-008 (female, 35-45) had osteoarthritic changes to the right knee. Three individuals had osteoarthritis of the ankle joints, HFE-A-004 (an adult of unknown age and sex), left ankle affected (see also discussion on fractures, section 4.2.3, and tibial periostitis, section 4.2.5), HFE-A-014e (male, 35-45), right ankle affected and HFE-A-016 (female, 25-35), both ankles affected, as well as the left foot (see also discussion on congenital disease, section 4.2.7).

Seven individuals had more than two joints affected. HFE-A-011 (male, 35-45) had bilateral osteoarthritic changes of the joints of the rib and vertebrae and the shoulder, as well as the right elbow being affected, both wrists and the right ankle and foot. In addition the manubrium and sternum were fused, which could be indicative of osteoarthritis. HFE-A-013 (female, 35-45) had osteoarthritic changes on the right

wrist and hand as well as the left ankle and both feet (see also discussion on fractures, section 4.2.3). HFE-A-014h (female, 35-45) had osteoarthritic changes to the right knee and both ankles. HFE-A-015 (female, 45+) had osteoarthritis in both shoulders and elbows, the left wrist and hand, both hips and an unsided foot. HFE-A-018 (male, 35-45) had

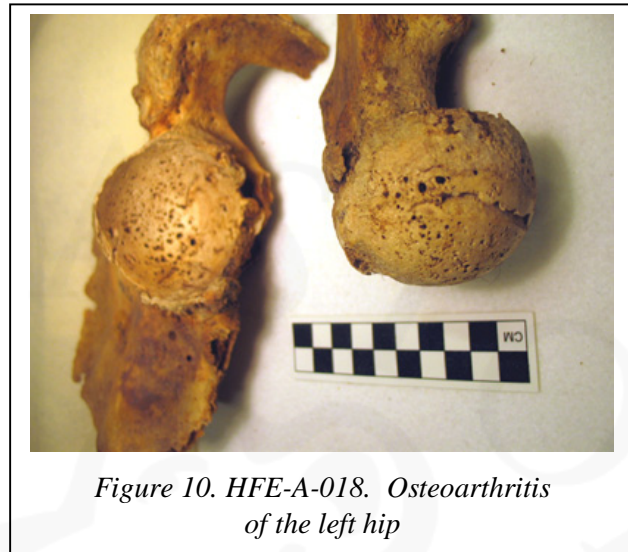

Figure 10. HFE-A-018. Osteoarthritis of the left hip

osteoarthritis in the joints of the ribs and vertebrae on the right side, both shoulders, wrists and hands. The left hip was also affected (see discussion on fractures, section 4.2.3 and figure 10) as well as both knees, ankles and feet. HFE-A-019 (male, 25-35) had bilateral osteoarthritis of the joints of the ribs and the vertebrae, as well as the right elbow and both feet.

Thirteen individuals have degenerative changes, i.e. osteophyte formation or increased porosity, which are not severe enough to diagnose osteoarthritis. These are in most instances part of the natural ageing process, or secondary to trauma. Three individuals have degenerative changes to the tempo-mandibular joint, two females, HFE-A-014f (25-35) and HFE-A-015 (45+), and one male, HFE-A-022 (35-45). Two individuals have degenerative changes to the vertebral-rib joints, HFE-A-011 (male, 35-45) and HFE-A-019 (male, 25-35). The latter also has changes to the sternal end of the 1st ribs. Two individuals have degenerative changes to the sternal ends of the clavicles, both males, HFE-A-014e (35-45) and HFE-A-019 (25-35).

Two individuals, both males, 35-45, have degenerative changes of the shoulder, HFE-A-014e and HFE-A-022. Six individuals have degenerative changes of the elbow, three females, HFE-A-014f (25-35), HFE-A-008 (35-45) and HFE-A-015 (45+), and three males HFE-A-019 (25-35) and HFE-A-011 & HFE-A-014e (35-45). Three individuals have degenerative changes to the wrists and hands, two females, HFE-A-016 (25-35) and HFE-A-015 (45+), and one male, HFE-A-018 (35-45).

HFE-A-013 (female, 35-45) and HFE-A-018 (male, 35-45) have degenerative changes to the knees, and seven have changes to the ankles and/or feet. These include three females, 35-45; HFE-A-008, HFE-A-013 and HFE-A-014h, three males, 35-45, HFE-A-014e, HFE-A-018 and HFE-A-022 and one adult of unknown sex and age, HFE-A-023

- *Total osteoarthritis (other than spine) 22.2%*
 - *Ribs 5.6%
 - *Sternum 1.9%
 - *Shoulder 7.4%
 - *Elbow 5.6%
 - *Hand/wrist 7.4%
 - *Hip 3.7%
 - *Knee 5.6%
 - *Ankle/feet 16.7%
- *Age related degenerative joint changes (other than spine)*
 - *TMJ 5.6%
 - *Ribs 3.7%
 - *Clavicle 3.7%
 - *Shoulder 5.6%
 - *Elbow 11.1%
 - *Hands/wrists 5.6%
 - *Knee 3.7%
 - *Ankle/feet 13.0%

4.2.5 OCCUPATIONAL STRESS INDICATORS

Four individual have slight periostitis isolated to the tibia. This is generally caused by recurrent minor trauma to the shins, where the tibia lies close to the skin surface, causing inflammation of the periostium. This is most likely to have been associated with occupation, and is common in agricultural communities (Roberts and Manchester, 1995). Those affected are HFE-A-004 (an adult of unknown age and sex), the left bone side only, the periostitis is active; HFE-A-014f (female, 25-35), bilateral healed periostitis; HFE-A-017a (4-8), the right tibia is affected, active and HFE-A-018 (male, 35-45), the right tibia side only, healed.

Enthesophytes are new bone formations within tendons or ligaments, and are usually associated with muscle strain. Three individuals; HFE-A-014f (female, 25-35), HFE-A-014h (female, 25-35) and HFE-A-018 (male, 35-45) have bilateral enthesophyte formation on the lateral epicondyle at the site of the attachment of the common

extensor tendon on the humerus, the attachment of muscles involved in the extension of the elbow.

Sesamoid bones are formed within tendons, and assist in mechanical action and pressure. They tend to form within the tendons of the hands and feet when they are subject to continued strain. Eight individuals have sesamoid bones in just the feet, each with 1-8 bones, between 8-15mm in diameter. Five women are affected, HFE-A-006 & HFE-A-007 (18-25) and HFE-A-008, HFE-A-013 & HFE-A-014h, two males, HFE-A-018 & HFE-A-022 (35-45) and one adult of unknown age and sex, HFE-A-023. One individual, HFE-A-011 (male, 35-45) has sesamoid bones in both the hands and the feet, and one, HFE-A-019 (male, 25-35) in just the hands.

Os acromiale or the non-fusion of the acromion of the scapula has been associated with strain on the shoulder. In the Haffjarðarey collection there are three individuals with *os acromiale*. In two instances it is bilateral, HFE-A-018 (male, 35-45) and HFE-A-020 (female, 35-45), and in one instance only the right shoulder is affected, HFE-A-008 (female, 35-45).

- *Tibial periostitis* 7.4%
- *Enthesopathies* 5.6%
- *Sesamoid bone, hands* 3.7%
- *Sesamoid bone, feet* 16.7%
- *Os acromiale* 5.6%

4.2.6 NEOPLASTIC DISEASE

There is one possible case of neoplastic disease in the Haffjarðarey collection. HFE-A-014h (female, 35-45) has an oval bone formation, 12x22mm on the left side of the frontal bone, 35mm above the orbit (see figure 11). The sclerotic bone has an uneven surface, is about 1mm thick and seems to sit in a slight depression. There

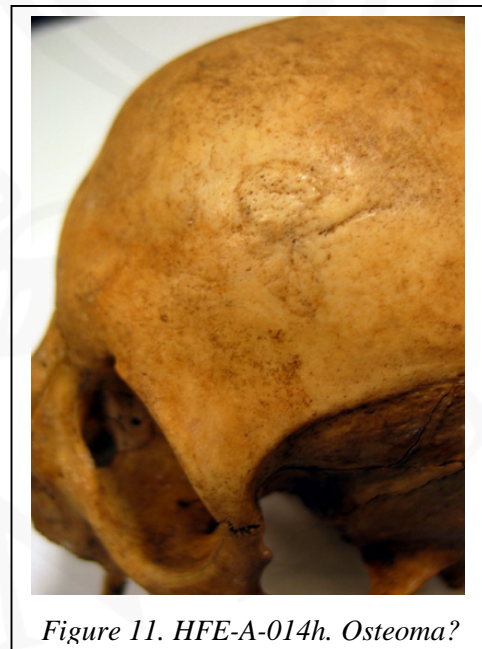

Figure 11. HFE-A-014h. Osteoma?

appears to have been an increased blood supply, with a large vein depression leading to the lesion. This is possibly an osteoma, however the irregularity of the new bone is uncharacteristic. This would need further analysis to confirm the diagnosis.

- *Button osteoma(?)* 1.9%

4.2.7 CONGENITAL DISEASE

Transitional vertebrae are vertebrae that incorporate the morphological characteristics of adjacent vertebrae. This is most commonly seen in the lumbar and sacral vertebrae (Aufderheide & Rodriguez-Martin, 1998), causing the sacrilisation of the 5th lumbar vertebrae (see figure 12), of which there is one case in the Haffjarðarey collection, HFE-A-016 (female, 25-35) or the lumbarisation of the 1st sacral vertebral segment, of which there is also one case, HFE-A-014f (female, 25-35).

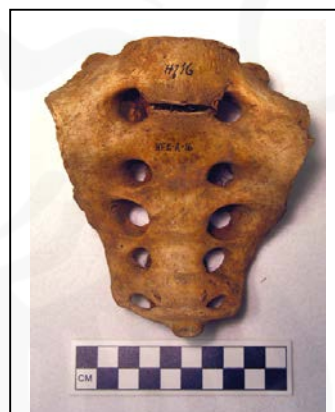

Figure 12. HFE-A-016.
Sacrilisation

Spina bifida occulta is a congenital condition where the posterior parts of some or all of the sacral vertebral segments are absent (see figure 13). One individual in the Haffjarðarey collection has this condition, HFE-A-015 (female, 45+).

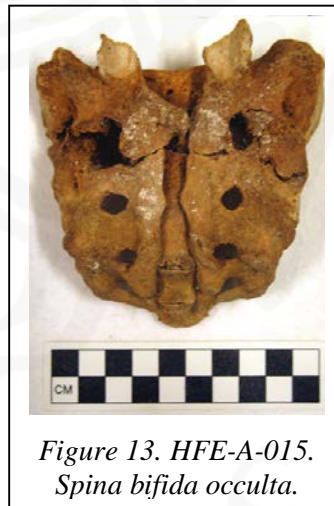

Figure 13. HFE-A-015.
Spina bifida occulta.

There is one further case of congenital disease in the collection. HFE-A-016 (female, 25-35) displays features indicating that this individual suffered from Marfan's syndrome. Marfan's syndrome is a defect in the cross-linking of the collagen fibrils, causing the loss of their triple-helical structure and therefore of their physical integrity. The weakening of the fibres of the aortic wall often results in a fatal aortic rupture in mid-adulthood. Skeletal changes include dolichocephaly and frontal bossing of the skull, excessively elongated extremities and arachnodactyly, kyphosis or scoliosis of the spine, *hallux valgus* and frequently dislocations due to weakened joint capsules (Aufderheide & Rodriguez-Martin, 1998). HFE-A-016

displays an antero-posterior shortening of the cranium, with elongation of the face and an unusually high palate (see figure 16). There are spinal problems, particularly in the lumbar vertebrae, with slight kyphosis of the spine. In addition the first metatarsal-phalange joints are osteoarthritic. Although her living stature at 162 ± 4 cm would not be considered unusually tall today, she is one of the tallest females in the collection. It is also worth noting that at 25-35 at the time of death, she is younger than the average life expectancy of the period (Jón Steffensen, 1975). Further analysis is required here, in particular accurate measurements of the hands and skull, to check whether she is dolicephalic and arachnodactalic.

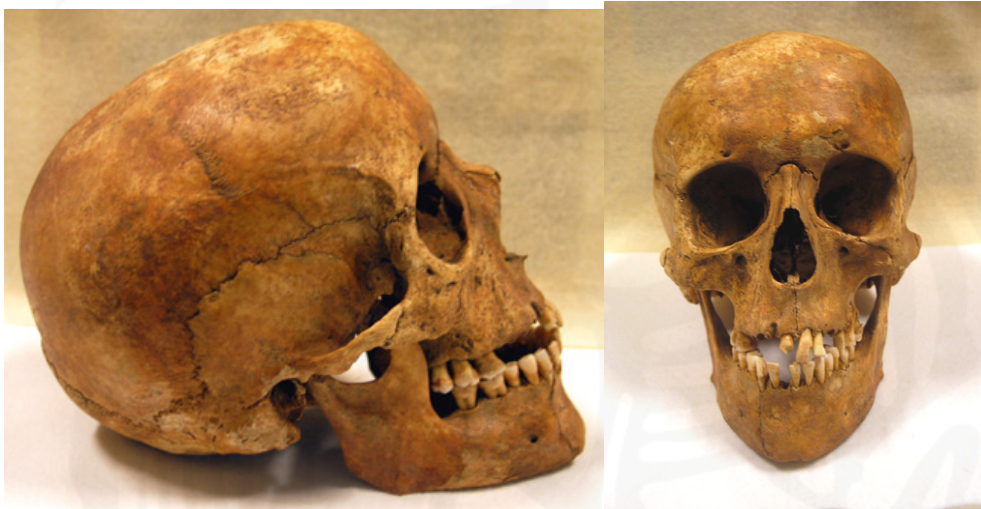

Figure 14. HFE-A-016. Shortened cranium and elongated face

- *Sacrilisation 1.9%*
- *Lumbarisation 1.9%*
- *Spina bifida occulta 1.9%*
- *Marfan's syndrome 1.9%*

4.2.8 NON-SPECIFIC STRESS INDICATORS

Enamel hypoplasias are linear or pitted dental defects that affect the enamel of teeth, if the child suffers some sort of stress during the time it is developing. These are usually associated with nutritional deficiency or childhood illness such as measles (Roberts and Manchester, 1995). Twelve individuals have enamel hypoplasia, 1-21 teeth being affected in each one. Linear defects are most common, seen in ten individuals; four juveniles, HFE-A-017a (4-8), HFE-A-021a, HFE-A-021b and HFE-A-026 (8-13); two females, HFE-A-024 (18-25), HFE-A-014f (25-35) and four males,

HFE-A-019 (25-35), HFE-A-014e, HFE-A-018 and HFE-A-022 (35-45). One individual has pitted defects in the enamel, HFE-A-011 (male, 35-34), and one, HFE-A-016 (female, 25-35), has a combination of pitted and linear defects (see also discussion on congenital disorders, section 4.2.7).

- *Enamel hypoplasia 22.2%*

4.2.9 DENTAL DISEASE

Periodontal disease starts with the inflammation of the soft tissue, which can eventually be transmitted to the bone and result in its resorption and eventually tooth loss. Periodontal disease is diagnosed where there is increased porosity of the alveolar bone, or subgingival calculus. Six individuals in the Haffjarðarey skeletal collection have periodontal disease. This includes two females HFE-A-034 (35-45) and HFE-A-015 (45+), and four males HFE-A-019 (25-35), HFE-A-011, HFE-A-014e and HFE-A-018 (35-45). In all cases both the maxilla and mandible are involved, except for HFE-A-034, where only the mandible was affected.

Anti-mortem tooth loss in adult individuals can be caused by several factors. It can be attributed to degenerative changes, periodontal disease or trauma. In the Haffjarðarey skeletal collection there are ten individuals who have suffered anti-mortem tooth loss of the permanent dentition. Three of these cases can be attributed to periodontal disease, HFE-A-011, HFE-A-015 and HFE-A-018. One case is secondary to an abscess, HFE-A-033, and two cases are caused both by periodontal disease and abscesses, HFE-A-019 and HFE-A-034. For further information on anti-mortem tooth loss, see table 5.

Skeleton	Sex	Age	Number of teeth lost	Skeleton	Sex	Age	Number of teeth lost
HFE-A-011	M	35-45	1	HFE-A-019	M	25-35	2
HFE-A-014h	F	35-45	13	HFE-A-020	F	35-45	11
HFE-A-015	F	45+	32	HFE-A-025	M	35-45	10
HFE-A-016	F	25-35	3	HFE-A-033	M?	45+	13
HFE-A-018	M	35-45	10	HFE-A-034	F	35-45	10

Table 5. HFE ante-mortem tooth loss

Only two individuals have possible carious lesions, HFE-A-014e (male, 35-45), on the interproximal surface of the right maxillary 1st premolar, and HFE-A-017a (4-8)

on the occlusal surface of the right maxillary 2nd deciduous molar. In addition this latter individual has severe attrition on the mandibular deciduous teeth.

Abscess formation in the alveolar bone is frequently associated with some other form of dental disease, carious lesions, calculus formation or periodontal disease, which have allowed for the bacteria to get into the bone. In the Haffjarðarey collection eight individuals have dental abscesses, in most cases just one, although one individual, HFE-A-022, has five separate lesions. Three individuals have dental abscesses secondary to periodontal disease. In one case the lesion is active (see figure 15); HFE-A-018 (male, 35-45); and the other two are healed, HFE-A-014e and HFE-A-019 (both males, 35-45). In three cases there is medium to heavy calculus formation associated with the abscess. In two cases the abscesses are healed, HFE-A-016 (female, 25-35) and HFE-A-022 (male, 35-45) and in one case active, HFE-A-034 (female, 45+). There are two cases where no clear cause for the abscess can be seen. HFE-A-014i (8-13) has a large active maxillary abscess, which has caused the bone above the left canine to the 2nd premolar to be completely resorbed and HFE-A-033 (male? 45+) has an active maxillary abscess.

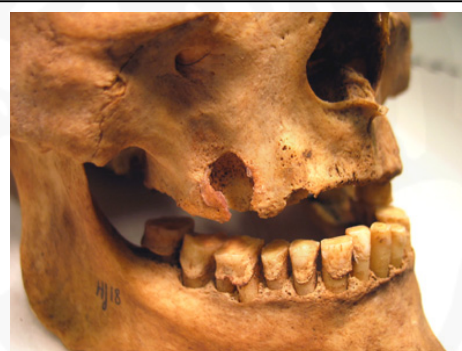

Figure 15. HFE-A-018. Dental abscess

A total of 328 teeth were recorded as having some calculus formation. The molars were most frequently affected, and the calculus formation was most commonly just

Skeleton	Sex	Age	Number of teeth affected	Skeleton	Sex	Age	Number of teeth affected
HFE-A-010	N/A	8-13	8	HFE-A-018	M	35-45	20
HFE-A-011	M	35-45	31	HFE-A-019	M	25-35	28
HFE-A-014e	M	35-45	32	HFE-A-020	F	35-45	13
HFE-A-014f	F	25-35	28	HFE-A-021a	N/A	8-13	15
HFE-A-014g	F	25-35	28	HFE-A-021b	N/A	8-13	20
HFE-A-014h	F	35-45	1	HFE-A-022	M	35-45	31
HFE-A-014i	N/A	8-13	7	HFE-A-024	F	18-25	9
HFE-A-014n	N/A	8-13	4	HFE-A-026	N/A	8-13	11
HFE-A-016	F	25-35	21	HFE-A-034	F	35-45	10
HFE-A-017a	N/A	4-8	11				

Table 6. HFE dental calculus.

flecks, 40.2%, 35.6% was medium calculus formation and 23.2% was heavy calculus formation. A total of 19 adults had calculus formation; the results are presented in table 6.

One individual, HFE-A-019 (male, 25-35) has an impacted tooth, the right maxillary 3rd molar. The tooth has not erupted and lies horizontally within the alveolar bone with the crown facing mesially.

- *Periodontal disease 11.1%*
- *Ante-mortem tooth loss 18.5%*
- *Caries(?) 3.7%*
- *Abscesses 14.8%*
- *Calculus 35.2%*
- *Impacted teeth 1.9%*

4.2.10 OTHER

HFE-A-025 (male, 35-45) has an enlarged incisive fossa, 9mm in diameter (see figure 16). A possible diagnosis for this is that it was caused by a nasopalatine duct cyst, which is believed to develop from epithelial remnants of oro-nasal ducts present in the incisive canal. Several aetiological factors have been suggested, trauma during mastication, bacterial infection, spontaneous proliferation, blockage of glandular ducts or genetic factors. Differential diagnoses of nasopalatine duct cysts include radicular cyst, odontogenic keratocyst and median palatine cyst (Velasquez-Smith *et al.*, 1999).



*Figure 16. HFE-A-025.
Nasopalatine duct cyst*

There are three further pathological cases of an uncertain aetiology that need reporting and which will need further study. The first case involves HFE-A-013 (female, 35-45) has an enlarged tubercle on the right 5th metatarsal. The second case is HFE-A-014f (female, 25-35) who has a hole (16x10mm) in the proximal central part of the blade of the left scapula. The edges are rounded, with clear evidence of healing, but there is no marginal bone formation. The third case involves the alveolar bone above

the 1st incisor to the canine and the nasal aperture of the right maxilla of HFE-A-034 (female, 35-45) has been completely resorbed with only the thin palate bone remaining (see figure 17). The right nasal aperture has been completely deformed inferiorly and to the right. The edges of the resorbed area are very sharp, with no marginal bone formation.

Whether this is caused by an infection or is some developmental defect is uncertain, it is worth noting however, that the left maxilla is completely unaffected.

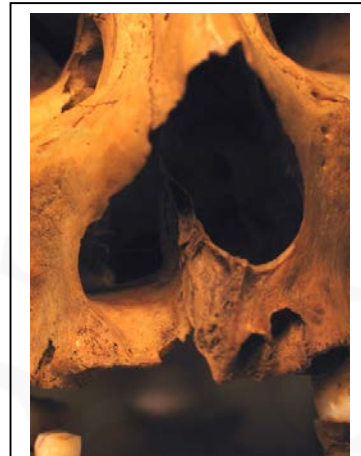


Figure 17. HFE-A-034. Abnormal nasal aperture.

- *Nasopalatine duct cyst 1.9%*

5 NEÐRANES, STAFHOLTSTUNGUM (NNS)

Human skeletal remains were recovered when the foundations for a new house were dug at Neðranes in 1980. Lilja Árnadóttir visited to the site, and discovered that the machine had disturbed most of the bones. No clear grave cuts could be seen, and it was assumed that these were bones that had been previously disturbed and reburied. Human skeletal remains had also been recovered in the first decade of the 20th century during construction work, and these had been reburied at the parish church at Stafholt. There are no documented records for the cemetery at Neðranes, and there was no stratigraphic dating evidence on site (Lilja Árnadóttir, 1982), however samples have been taken from NNS-A-001, NNS-A-002, NNS-A-005, NNS-A-006 and NNS-A-007 for carbon dating, and hopefully these will be published soon. It is unlikely however that a cemetery had been at Neðranes before the ownership of the land fell to Stafholt parish, so that it is likely that the Neðranes cemetery would have been abandoned by the 16th century (Lilja Árnadóttir, 1982).

5.1 THE MATERIAL

For further detail see appendix C

5.1.1 PRESERVATION

Preservation	
>90%	0
75-90%	0
50-75%	4
30-50%	3
<30%	1

Table 7. NNS preservation

Eight skeletons from the Neđranes site are preserved in the National Museum. The preservation of the bones within the collection is excellent, however there are several bones missing from each skeleton. The preservation of the material is shown in table 7. Of the eight skeletons in the collection, 50% have over 50% preservation.

5.1.2 AGE

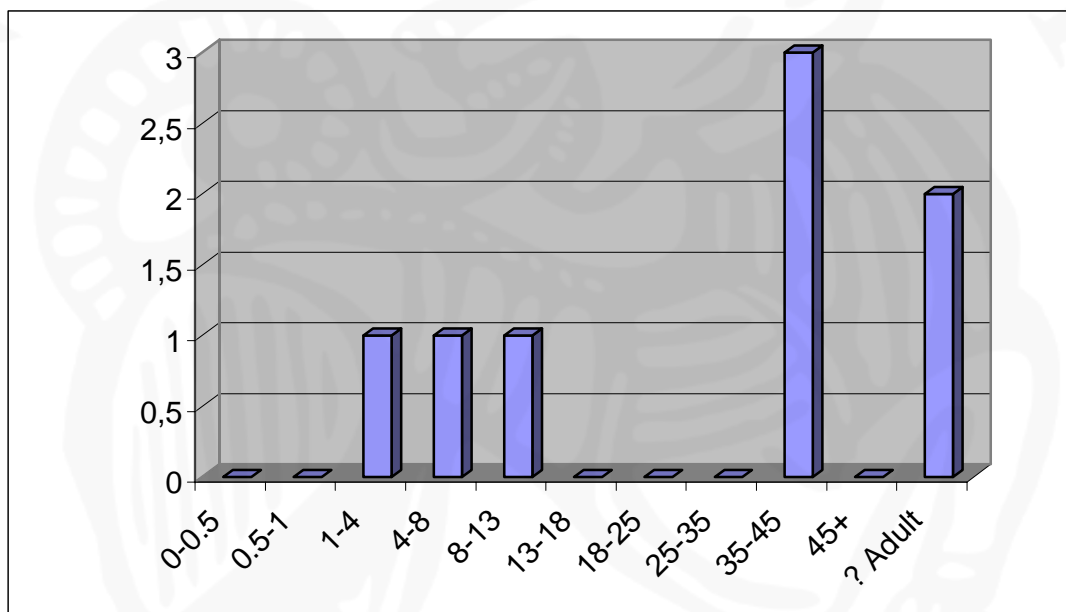


Figure 18. NNS age

Three of the eight skeletons in the Neđranes collection are juveniles. However the number of individuals is too low for this to have any statistical significance. Of the five adults, two could not be sexed. For the division of age, see figure 18.

5.1.3 SEX

Of the five adults in the Neđranes population, one could not

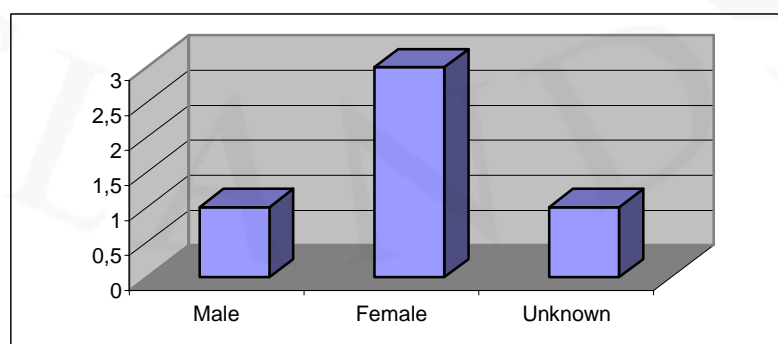


Figure 19. NNS sex

be sexed. The results are shown in figure 19. Again, the numbers here are too few to have any statistical significance.

5.1.4 STATURE

Four of the five adults were preserved well enough to allow for stature measurements. The number of individuals here is too low to represent graphically, see appendix C for further detail.

5.2 PALAEOPATHOLOGY

5.2.1 INFECTIOUS DISEASE

There are two possible cases of infection in the Neðranes collection. NNS-A-003 (1-4) has an area of increased porosity on the frontal bone, superior to the nasal spine. The pores are c. 1mm in diameter with rounded edges. It is possible that this indicates the presence of sinusitis, although this would have to be confirmed with further analysis. NNS-A-006 (female, 35-45) has an area of increased porosity in the anterior part of the palate, probably caused by some infection.

- *Sinusitis(?)* 12.5%
- *Non-specific infection* 12.5%

5.2.2 TRAUMA

One individual, NNS-A-001 (8-13), has bilateral *osteochondritis dissecans* of the distal end of both humeri.

- *Osteochondritis dissecans, elbow* 12.5%

5.2.3 JOINT DISEASE

5.2.3.1 SPINAL JOINT DISEASE

Two individuals in the collection have spinal osteoarthritis, diagnosed either if there is eburnation, or two other features of degenerative joint disease, osteophytes, porosity or fusion. NNS-A-005 (male, 35-45) has osteoarthritis of the cervical vertebrae and NNS-A-007 (adult female of an unknown age) of the lumbar vertebrae. In addition NNS-A-007 has Schmorl's nodes of the thoracic vertebrae.

Other degenerative changes of the spinal joints are common; all the adults in the collection with preserved vertebrae have some degenerative spinal changes.

- *Osteoarthritis, cervical vertebrae 12.5%*
- *Osteoarthritis, lumbar vertebrae 12.5%*
- *Schmorl's nodes, thoracic vertebrae 12.5%*

5.2.3.2 OTHER JOINT DISEASE

One individual, NNS-A-005 (male, 35-45) has osteoarthritis of the left rib – vertebral joints. Degenerative changes include NNS-A-005 (male, 35-45) of both 1st rib – manubrium joints and NNS-A-007 (adult female of unknown age) of the right knee.

- *Total osteoarthritis (other than spine) 12.5%*
**Ribs 12.5%*
- *Age related degenerative joint changes (other than spine) 25.0%*
**Ribs 12.5%*
**Knee 12.5%*

5.2.4 NON-SPECIFIC STRESS INDICATORS

Two individuals in the Neđranes collection have enamel hypoplasia, or lines of arrested growth within the enamel indicative of stress during childhood, usually associated with nutritional deficiencies. Those affected are NNS-A-004 (4-8), pitted hypoplasias on the left maxillary 2nd deciduous molar, and NNS-A-006 (female, 35-45), linear hypoplasias on the left mandibular 1st incisor and canine.

- *Enamel hypoplasia 25.0%*

5.2.5 DENTAL DISEASE

Two individuals have anti-mortem tooth loss, NNS-A-005 (male, 35-45), 2 teeth lost and NNS-A-006 (female, 35-45), 3 teeth lost. There are no other changes, i.e. periodontal disease or abscesses, which indicate why the teeth were lost.

Three individuals have calculus formation in a total of 28 teeth. Of those, 39.3% have flecks of calculus, 46.4% have medium calculus formation and 14.3% have heavy calculus formation. Those affected are NNS-A-004 (4-8), three teeth, NNS-A-005

(male, 35-45), six teeth and NNS-A-006 (female, 35-45), nineteen teeth. The latter also have some crowding of the right mandibular incisors.

- *Ante-mortem tooth loss* 25.0%
- *Calculus* 37.5%
- *Crowding* 12.5%

6 VIÐEY, KOLLAFIRÐI (VEY)

Earliest records indicate that the first church in Viðey was built around 1200, and that at least four churches were built prior to the church that stands in the island today.

The cemetery has probably been in use since that time (Margrét Hallgrímsdóttir, 1993), with the latest burial there dating to 1999. The excavations in the cemetery in Viðey were carried out 1987 – 1988, directed by Margrét Hallgrímsdóttir. A total of 91 graves were excavated, 60 in the 1987 season and 31 in the 1988 season. There was much intercutting of graves due to the long period of use of the cemetery. The earliest graves excavated were orientated northwest-southeast, like the remains of what has been interpreted as the Viðey cloister, but the latest ones like Viðey church, which was built in 1774. The skeletons preserved in Árbæjarsafn are from this later period, and are all dated by the excavator to the 18th and 19th century. (Margrét Hallgrímsdóttir, 1989; 1993).

6.1 THE MATERIAL

For further detail see appendix D.

6.1.1 PRESERVATION

The preservation of the material from the Viðey cemetery is very varied. Some skeletons are excellently preserved, while only a few fragments

Preservation	
>90%	9
75-90%	5
50-75%	4
30-50%	7
<30%	12

Table 8. VEY preservation

represent others. These are probably disturbed bones contained within later grave cuts, which have been given unique numbers.

The preservation of the material is summed up in table 8. Of the 37 skeletons in the collection, 48.6% have 50% or more preservation.

6.1.2 AGE

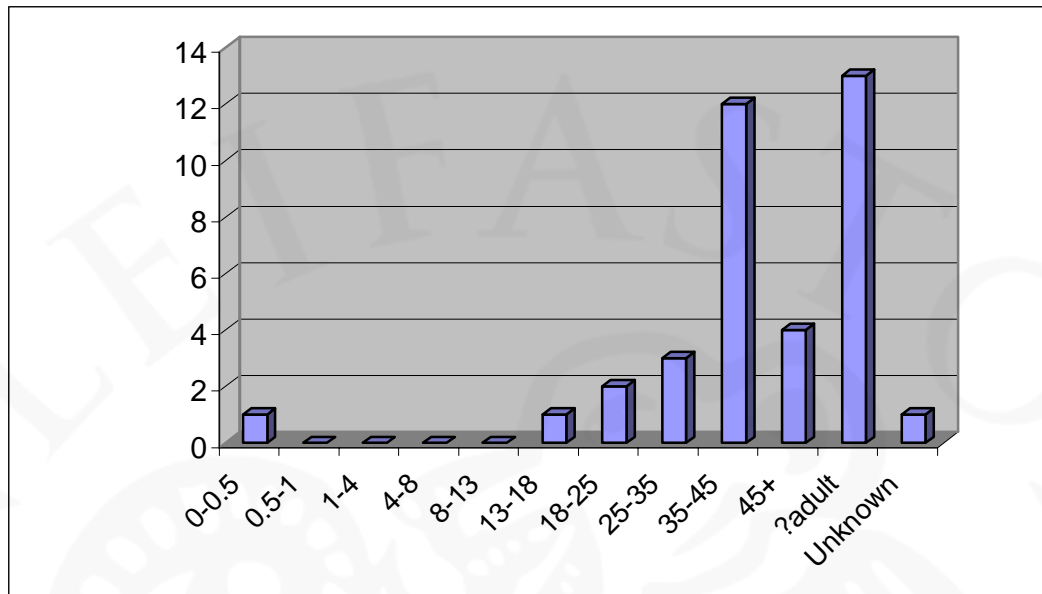


Figure 20. VEG age

Two skeletons in the VEG collection were juveniles. Thirteen of the adult skeletons were too poorly preserved to determine their age, and one skeleton in the collection was too poorly preserved to determine whether it was an adult or a juvenile. A summary of the age is presented in figure 20.

6.1.3 SEX

Of the 34 adult skeletons in the collection, six were too poorly preserved to diagnose the sex. There is a higher percentage of male skeletons, 50% to 32.2% females, probably reflecting a bias in the sampling, rather than the actual male – female ratio. The result for the sexing is shown in figure 21.

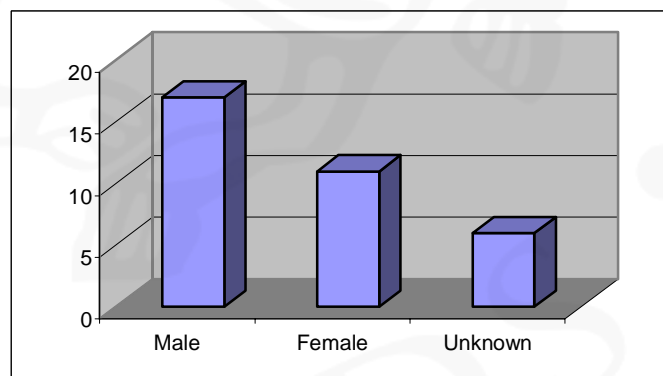


Figure 21. VEG sex

6.1.4 STATURE

Of the 34 adults in the Višey collection, the stature could be calculated for 19. The results are presented in figure 22.

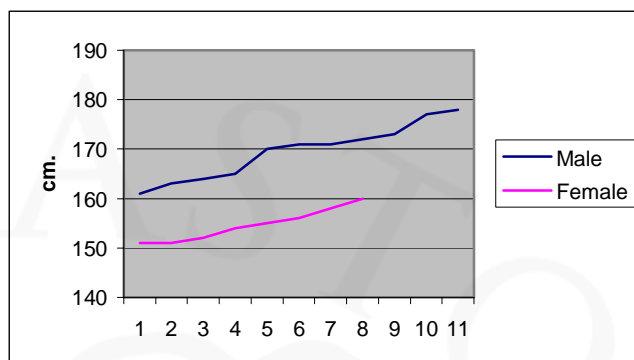


Figure 22. VEY stature

6.2 PALAEOPATHOLOGY

As already stated, the summary of each pathology is presented as a percentage of the whole population, however, one skeleton in the Višey collection (VEY-A-010) was too poorly preserved to even be certain that the bones were human, so it is not included in the percentage calculations.

6.2.1 NUTRITIONAL DISEASE

Four individuals have *cribra orbitalia* indicative of iron deficiency anaemia. These are VEY-A-001 & VEY-A-013 (females, 35-45), VEY-A-007 (female, 45+) and VEY-A-023 (13-18)

- *Cribra orbitalia* 11.1%

6.2.2 INFECTIOUS DISEASE

Twelve individuals in the Višey collection have an infectious disease involving bone. One individual has changes suggesting possible tuberculosis (bovine?). VEY-A-001 (male, 35-45) has an abscess in the left lateral crest of the sacrum, with a 7mm cloaca inferior to the auricular surface.

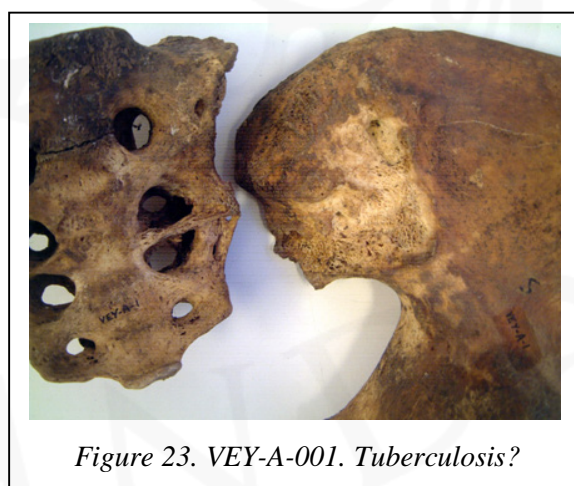


Figure 23. VEY-A-001. Tuberculosis?

The edges of the cloacae are rounded, suggesting that the infection had healed at the time of death. The infection has caused the sacrum to become fused to the left os coxa (see figure 23), although this has been broken post-mortem.

One individual VEY-A-021b (male, 45+) has changes indicative of syphilis. The most diagnostic features of this are the *caries sicca* of the frontal bone (see figure 24).

The lesions have not yet pierced the surface, but form confluent clustered pits, concentrated on the area superior to the glabella and the lateral portion of the frontal bone. There is also some resorption of the inferior part of the nasal aperture and the nasal spine (see figure 24), as well as a slight increase in porosity of the

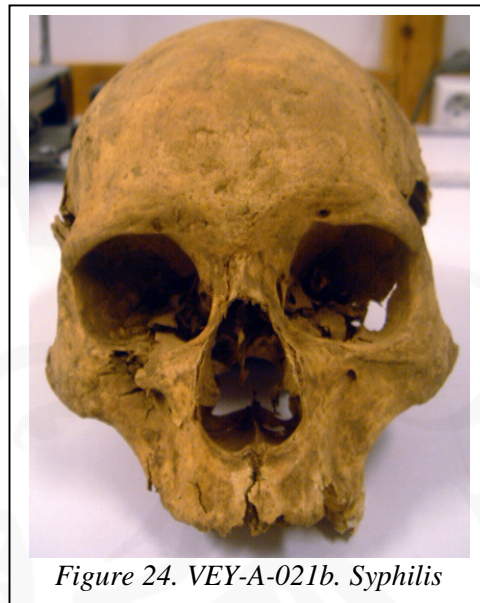

Figure 24. VEY-A-021b. Syphilis

premaxillary suture. Several other bones show non-specific infectious disease changes, probably due to the syphilis as well: increased porosity and spiculed new bone formation around and inferior to the notch in the lamina of the 6th thoracic vertebrae; three 3rd-10th right ribs with active new bone formation on the inner side near the sternal end; lamellar bone on entire palmar surface of shaft of a left proximal phalange; lamellar bone on distal half of the anterior surface of both femoral shafts and lamellar bone on proximal half of the lateral surface of both tibial shafts.

In addition, five individuals have new bone formation on the ribs indicative pulmonary disease, for example pneumonia or bronchitis. These are two males, 35-45, VEY-A-026, with healed new bone formation on the anterior border, near the sternal end, of two 3rd-10th right ribs & VEY-A-029 (see also discussion on periostitis and non-specific infections, both this section) with active new bone formation on central parts of inner side of four ribs (see figure 25); VEY-A-021 (female, 35-45), with active new bone formation on the inner border of one 3rd-10th right rib (see also discussion on periostitis, this section); VEY-A-015 (male, 18-25), with active new

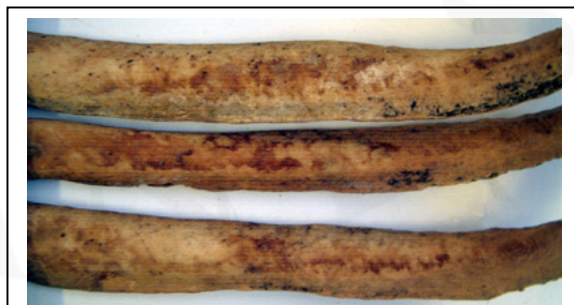

Figure 25. VEY-A-029. Pulmonary disease.

bone formation on the inner border of six right and five left 3rd-10th ribs and VEY-A-023 (13-18), who has active new bone formation on inner border of one right 3rd-10th rib.

Six individuals show changes indicating periostitis. These include three males, 35-45, VEY-A-003 has active new bone formation along the interosseous border of entire shaft of the left ulna; VEY-A-017 has healed new bone formation along the entire anterior part of shaft of both femora and tibiae, and VEY-A-029 (see also discussion on pulmonary disease and non-specific infection, both this section), has healed new bone formation on the medial surface of the central third of the shaft of the right tibia; VEY-A-023 (13-18), has healed new bone formation along the entire length of the shaft of both femora, tibiae and fibulae (see also discussion on pulmonary disease and non-specific infections, both this section); VEY-A-030, (male?, unknown age) has healed new bone formation along the lateral side of the entire length of the shaft of both tibiae (see also discussion on non-specific infection, this section), and VEY-A-021 (female, 35-45) has active new bone formation along lateral border of palate/lingual side of alveolar bone, area 10x23mm in size (also discussion on pulmonary disease, this section).

One individual, VEY-A-007 (female, 45+) has a possible parasitic infection. This is seen in the form of a large calcified mass, which was found in the right side of the thoracic cavity (see figure 26). The mass is broken post-mortem, but would have been quite large, c. 150mm in diameter. A possible diagnosis for this would be *Echinococcosis*, or tapeworm. This is usually diagnosed palaeopathologically through the presence of mineralised outer shells hydatid cysts. The *Echinococcus* worm lives in the intestines of dogs and foxes, and the parasitic eggs are passed to humans through contamination of food or water by faeces. Historically Iceland had the highest incidence of *Echinococcosis* in Europe (Ortner & Putschar, 1981; Roberts & Manchester, 1995).

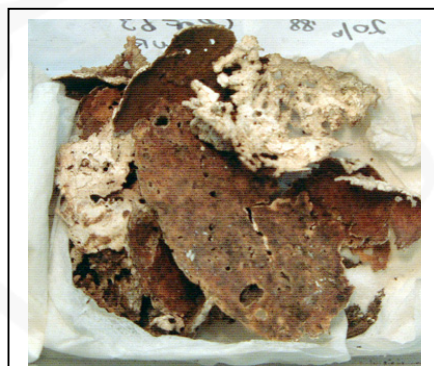

Figure 26. VEY-A-007.
Echinococcosis?

Four individuals have other cases of non-specific infection. Two of these are females, 45+; VEY-A-004 has a healed, well remodelled sclerotic bony formation on the internal surface of the frontal bone, just right of the midline on the superior part of the bone. The new bone formation is circular, 7mm in diameter and 3mm thick. It is isolated and its surface is very uneven, forming spicules. VEY-A-007 has healed sclerotic new bone formation on the ventral part of the pubis. VEY-A-023 (13-18) has increased porosity of the plantar surface of the proximal half of both 5th metatarsals (see also discussion on pulmonary disease and periostitis, both this section). A possible cloaca, 3mm in diameter, is on the proximal end of the right bone. VEY-A-029 (male, 35-45) has a small circular area, 18mm in diameter, of porous destruction in the centre of the blade of the left scapula (see also discussion on pulmonary disease and periostitis, both this section), and VEY-A-030 (male, unknown age) has possible active woven bone formation on the internal side of the parietal bone along the sagittal suture (see also discussion on periostitis, this section).

- *Tuberculosis (bovine?)* 2.8%
- *Syphilis* 2.8%
- *Pulmonary disease* 11.1%
- *Periostitis* 20.7%
- *Echinococcosis* 2.8%
- *Non-specific infectious disease* 11.1%

6.2.3 TRAUMA

A total of eight individuals have fractures of bones. One individual, VEY-A-029 (male, 35-45) has a fracture of the distal third of the right nasal bone (see figure 27), extending round to the distal right side corner of the left nasal bone. The fragment has been displaced slightly to the left with a small hole in the right bone (7mm long) and a depression formed in the fragment of the right nasal bone. He also has a fracture of two right 3rd-10th ribs near the angle. Both have long standing compact bone formation along the fracture lines, and there has been a slight superior displacement of the fragments. The nasal and rib

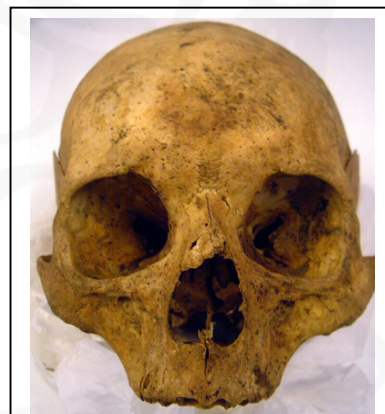

Figure 27. VEY-A-027.
Nasal fracture.

fractures are all long standing, and probably a result of the same traumatic event (see also discussion on soft tissue trauma, this section).

Three individuals have vertebral fractures. VEY-A-014 and VEY-A-012 (male, 35-45) have compression fractures of the thoracic vertebrae with scoliosis. In the case of VEY-A-014, the 7th and 8th are involved, and the 8th-10th in the case of VEY-A-012. One individual, VEY-A-021b (male, 45+) has a complete fracture with non-union of the left superior process of the 5th lumbar vertebrae. This is known as spondylolysis.

Two individuals have fractured clavicles. Both are males (35-45), The right clavicle of VEY-A-003 is 50mm shorter than the left one. This is the result of a possible fracture at the acromial end, medial to the conoid tubercle. If this were the case then it would have occurred in early childhood, as no new bone formation is visible. VEY-A-026 has a fracture across the sternal end of the right clavicle, across the line of the coracoid tubercle, with a slight anterior displacement of the sternal end. This fracture is long standing, with little new bone formation surrounding the fracture line. The same individual has a complete fracture with reunion of the dorsal part of the proximal articular surface of an unsided upper proximal phalange. Both these fractures are long standing, and probably a result of the same traumatic event. VEY-A-015 (male, 18-25) also has a fracture of an unsided upper proximal phalange, an oblique fracture from 7mm below the head to 6mm above the proximal articular surface. The fracture is long standing, well healed, and only very slightly displaced.

Two individuals have patellar fractures; VEY-A-016 (female, 45+) appears to have fractured the medial border of the left patella with non-union of the fragment and sclerotic bone formation along the fracture line. Possibly the area has necrosed. VEY-A-021b (male, 45+) has complete fragmentation with reunion of the fragment, of the medial side of the left patella (see also discussion on vertebral fractures, this section). There has been slight distal displacement of the fragment.

There is one case of foot or ankle fracture, VEY-A-004 (female, 45+) has a healed fracture of the right calcaneus, where the posterior part of the bone has broken off completely, but with reunion, so that the cuboid articular surface faces more proximally than it should (see figure 28). This has led to the complete destruction of

all the articular surfaces of the right ankle (see also discussion on joint disease, section 6.2.4.2).

All the fractures recorded in the Viðey collection are healed, long before death.




Figure 28. VEY-A-004. Calcaneal fracture

The right elbow of VEY-A-001 (male, 35-45) has subluxed slightly laterally. There is a pseudoarthrosis on the ulna, distal to radial notch, anterior to supinator crest. It is 24x13mm in diameter and corresponds with radial tuberosity. The radius has a corresponding pseudoarthrosis anterior to radial tuberosity, 23x9mm in diameter. This is a long-standing condition.

There are four possible cases of *osteocondritis dissecans* caused by death of bone tissue due to obliteration of blood supply, usually because of trauma (Roberts and Manchester, 1995). Two of these are males (35-45), VEY-A-026, who has a 8mm wide depression on the medial side of the trochlear surface of the left talus, with a reunited fragment, and VEY-A-012, who has circular porous depressions, 11mm in diameter on the lateral border of the posterior talar articular surface of both calcanei. VEY-A-023 (13-18) has circular depressions in the centre of posterior articular surfaces of both naviculars. The bilateral nature of the latter two suggests that they are possibly not *osteocondritis dissecans*.

There is one case of possible soft tissue trauma; VEY-A-029 (male, 35-45) has a spicule of new bone, 4mm in diameter, 4mm high, with a flattened head, distal to the medial epicondyle on the left femur. This is possibly due to trauma to the *adductor magnus*, which assists in the medial rotation of the femur (see also nasal and rib fraction, this section).

- Total fractures 31%
 - *Nasal 2.8%
 - *T. vertebrae 5.6%
 - *L. vertebra spondylolysis 2.8%
 - *Rib 2.8%
 - *Clavicle 5.6%

- **Hand/wrist* 5.6%
- **Patella* 5.6%
- **Foot/ankle* 2.8%
- *Subluxation* 2.8%
- *Osteochondritis dissecans* 8.3%
- *Soft tissue damage* 2.8%

6.2.4 JOINT DISEASE

6.2.4.1 SPINAL JOINT DISEASE

Seven individuals in the Viđey collection had osteoarthritis of the spinal column. Osteoarthritis was diagnosed where eburnation was present, or at least two other features of joint changes, osteophytes, porosity or fusion, are present to some degree. Six individuals have osteoarthritis of the cervical vertebrae, VEY-A-005 (female, 25-35), VEY-A-007 (female, 45+), VEY-A-029 (male, 35-45), and three of these also have osteoarthritis of the thoracic vertebrae, VEY-A-003 (male, 35-45), VEY-A-014 (female, 35-45) and VEY-A-021 (female, 35-45). One individual, VEY-A-004 (female, 45+) has osteoarthritis of the lumbar vertebrae.

Schmorl's nodes are changes on the vertebral body surfaces, usually affecting the thoracic and lumbar vertebrae, associated with the degeneration of the intervertebral disks. Their specific aetiology is uncertain, but trauma is frequently implicated (Roberts & Manchester, 1995). Three individuals have Schmorl's nodes on just the thoracic vertebrae, VEY-A-001 (male, 35-45), VEY-A-004 (female, 45+) and VEY-A-005 (female, 25-35), and six on both thoracic and lumbar vertebrae, VEY-A-003 (male, 35-45), VEY-A-006 (male, 25-35), VEY-A-012 (male, 35-45), VEY-A-014 (female, 35-45), VEY-A-015 (male, 18-25) and VEY-A-020 (female, 25-35).

Other joint changes, such as slight increase in porosity or osteophyte formation, which are not severe enough to be classed as osteoarthritis, were very common features. In fact all the adult skeletons that had vertebrae preserved had some degenerative spinal changes, apart from one individual, and in that case only fragments of the 1st - 4th cervical vertebrae have been preserved. These changes can be classed as normal degenerative changes caused by age and stress.

- *Osteoarthritis, cervical vertebrae* 16.7%
- *Osteoarthritis, thoracic vertebrae* 8.3%

- *Osteoarthritis, lumbar vertebrae 2.8%*
- *Schmorl's nodes, thoracic vertebrae 25.0%*
- *Schmorl's nodes, lumbar vertebrae 16.7%*

6.2.4.2 OTHER JOINT DISEASE

Six individuals have osteoarthritic changes in joints other than the spinal joints.

Osteoarthritis is diagnosed where there is eburnation, or two other severe degenerative joint changes (for example osteophyte formation and increased porosity).

VEY-A-006 (male, 25-35) has the manubrium and the sternum have fused together. There is no indication of trauma, so this is diagnosed as joint disease. VEY-A-001 (male, 35-45) has eburnation of the left elbow. This is secondary to a subluxation of the joint (see discussion on trauma, section 6.2.3). Two individuals have osteoarthritis of the hand and/or wrist, VEY-A-005 (female, 25-35) has slight eburnation of the distal articular surface of the right hand, and VEY-A-029 (male, 35-45) has severe eburnation of the carpals, metacarpals and phalanges of both hands (see also discussion of the lower limb, this section).

Two individuals have osteoarthritis of the knee, in both cases eburnation of the left joint, VEY-A-014 (female, 35-45) and VEY-A-004 (female, 45+). The latter also has severe eburnation and osteophyte formation of all the bones of the right ankle. These arthritic changes are probably secondary to a severe fracture of the left calcaneus (see discussion on trauma, section 6.2.3). VEY-A-029 (male, 35-45) has bilateral eburnation of the several tarsal bones and VEY-A-007 (female, 45+) has eburnation of the proximal joint of the 4th left metatarsal.

Ten individuals show age related degenerative joint changes, mostly osteophyte formation and increased porosity, which are not severe enough to diagnose osteoarthritis.

One individual, VEY-A-007 (female, 45+) has increased porosity of the head of the first left rib.

Four individuals have osteophyte and/or increased porosity of one or both shoulder joints. These are three females VEY-A-002, VEY-A-021 (35-45) and VEY-A-007

(45+) and one male VEY-A-003 (35-45). Four individuals have degenerative changes to one or both elbows. These are two females, VEY-A-004 & VEY-A-007 (45+), and two males, VEY-A-026 & VEY-A-029 (35-45). One female, VEY-A-004 (45+), has degenerative changes to both wrists.

Two females, VEY-A-004 & VEY-A-007 (45+), have osteophyte formation and increased porosity of both hips. Two females have degenerative changes of the knee, bilateral in the case of VEY-A-004 (45+) and the right knee in the case of VEY-A-014 (35-45). VEY-A-007 (female, 45+) has bilateral degenerative changes on both ankles. VEY-A-002 (female, 35-45), who has two lower middle and distal phalanges fused to each other. There is no indication for any trauma that could have caused this so it is recorded as a joint disease.

- *Total osteoarthritis (other than spine)*
 - *Sternum 2.8%
 - *Elbow 2.8%
 - *Hand/wrist 5.6%
 - *Knee 5.6%
 - *Foot/ankle 11.1%
- *Age related degenerative joint changes (other than spine)*
 - *Ribs 2.8%
 - *Shoulder 11.1%
 - *Elbow 11.1%
 - *Hands/wrists 2.8%
 - *Hips 5.6%
 - *Knee 5.6%
 - *Ankles 2.8%

6.2.5 OCCUPATIONAL STRESS INDICATORS

Six individuals have between 1-3 sesamoid bones of the feet, 10-15mm in diameter. These are VEY-A-001 (male, 35-45), VEY-A-002 (female, 35-45), VEY-A-006 (male, 25-35), VEY-A-007 (female, 45+), VEY-A-026 (male, 35-45) and VEY-A-029 (male, 35-45). Sesamoid bones are formed within tendons and assist in mechanical action and pressure. These can form within the tendons in the hand and feet when they are under excessive strain.

Other occupational stress indicators are bilateral grooves within intertubercular groove of both humeri of two individuals, VEY-A-006 (male, 25-35) and VEY-A-015 (male, 18-25), suggesting excess strain on the *latissimus dorsi* and *pectoralis major*

muscles, which are involved in extension, adduction and medial rotation of the shoulder. In addition two individuals have the formation of pseudoarthrosis on the shoulder, VEY-A-007 (female, 45+), bilateral pseudoarthrosis formation on the accromion of the scapula, and VEY-A-021 (female, 35-45), bilateral pseudoarthrosis formation on the accromial end of the clavicle.

- *Sesamoid bone, feet* 20.7%
- *Muscle stress, shoulder* 5.6%
- *Pseudoarthrosis, shoulder* 5.6%

6.2.6 NEOPLASTIC DISEASE

One individual, VEY-A-029 (male, 35-45), has a benign neoplasm, button osteomas on the frontal bone. There are two separate bone growths, each 3mm in diameter.

- *Button osteoma* 2.8%


6.2.7 CONGENITAL DISEASE

One individual, VEY-A-006 (male, 35-45) has lumbarisation of the 1st sacral segment, with partial separation from the rest of the sacrum. Two males have *spina bifida occulta*, VEY-A-003 (35-45) and VEY-A-015 (18-25). In both cases the neural arches of the 3rd – 5th sacral segments have failed to fuse. The neural arch of C2 has failed to fuse in one individual, VEY-A-002 (female, 35-45). This is possibly a case of so called butterfly vertebra, although it is more common for the thoracic or lumbar vertebrae to be affected (Aufderheide & Rodriguez-Martin, 1998).

- *Lumbarisation* 2.8%
- *Spina bifida occulta* 5.6%
- *Butterfly vertebrae* 2.8%

6.2.8 METABOLIC AND ENDOCRINE DISEASE

There are three possible cases of high uric acid. One female (35-45), VEY-A-014, has a urinary calculi, 6cm in diameter (see figure 29). There are also two possible cases of gout. One possible case is a female (35-45), VEY-A-002, who has



small localised lesions on the distal epiphysis of the first left metatarsal and two lower middle phalanges. A much more likely candidate is VEY-A-015 (male, 18-25) who has a large circular localised porous lesion, 15mm in diameter on the distal epiphysis of the right first metatarsal.

- *Urinary calculi 2.8%*
- *Gout 5.6%*

6.2.9 NON-SPECIFIC STRESS INDICATORS

Enamel hypoplasia are linear or pitted dental defects that affect the enamel of teeth while they are developing, if the child suffers some sort of stress during that time. These are usually associated with nutritional deficiency or childhood illness such as measles (Roberts and Manchester, 1995). Twelve individuals have enamel hypoplasia, involving between two and twenty-one teeth. In all except one case the hypoplasias are linear, in one case (VEY-A-001) it is pitted. Of those affected there are ten males; VEY-A-015 (18-25); VEY-A-006 (25-35); VEY-A-001, VEY-A-003, VEY-A-012, VEY-A-017, VEY-A-026, VEY-A-028 & VEY-A-029 (35-45) and VEY-A-031 (unknown age). Two females are affected, VEY-A-020 (25-35) and VEY-A-021 (35-45).

Harris lines of arrested growth are formed in the long bones in the same way as enamel hypoplasia in teeth, and can be detected in X-rays. Two skeletons from the Viðey collection have had long bones X-rayed, VEY-A-007 (female, 45+), the right humerus, radius, ulna, femur, tibia and fibula. Harris lines were seen in the distal radius, and in both metaphyses of the tibia and fibula. VEY-A-021b (male, 45+) had the left femur and tibia X-rayed, and Harris lines were seen in both metaphyses of the tibia. These results will not be presented as percentages, as only two skeletons have had long bones X-rayed.

- *Enamel hypoplasia 36.1%*

6.2.10 DENTAL DISEASE

Eight individuals suffer from periodontal disease. This disease process starts with the inflammation of the soft tissues, gingivitis, commonly due to calculus formation,

which can eventually transmit to the bone, resulting in resorption of the alveolar bone, and eventual tooth loss (Roberts & Manchester, 1995). Of the periodontal disease cases seen in the Viðey collection, three individuals have subgingival calculus formation, on both the mandible and maxilla in the case of VEY-A-006 (male, 25-35) and VEY-A-007 (female, 45+), and just on the mandible in VEY-A-014 (female, 35-45). One individual has just resorption of the alveolar bone of the mandible and maxilla, VEY-A-031 (adult male, unknown age). However, five individuals have both subgingival calculus and resorption of the alveolar bone. This affects both the maxilla and mandible in VEY-A-021 (female, 35-45), VEY-A-026 and VEY-A-029 (males, 35-45), but just the mandible in VEY-A-005 (female, 25-45).

A total of sixteen individuals have suffered ante-mortem tooth loss. In five cases the tooth loss is secondary to periodontal disease. VEY-A-005, VEY-A-007, VEY-A-021, VEY-A-029, and VEY-A-031. In other instances this is most likely to be related to old age, although there are some possible occurrences of accidental tooth loss. However, there are no bony changes suggesting that. Those affected are shown in table 9.

Skeleton	Sex	Age	Number of teeth lost	Skeleton	Sex	Age	Number of teeth lost
VEY-A-002	F	35-45	2	VEY-A-016	F	45+	9
VEY-A-003	M	35-45	6	VEY-A-020	F	25-35	1
VEY-A-004	F	45+	13	VEY-A-021	F	35-45	9
VEY-A-005	F	25-35	10	VEY-A-021b	M	45+	1
VEY-A-007	F	45+	16	VEY-A-026	M	35-45	28
VEY-A-011	?	?adult	1	VEY-A-028	M	35-45	6
VEY-A-014	F	35-45	5	VEY-A-029	M	35-45	2
VEY-A-015	M	18-25	1	VEY-A-031	M	?adult	2

Table 9. VEY ante-mortem tooth loss.

Five individuals have carious lesions in a total of 19 teeth. The caries is most commonly seen on the occlusal surface or the cervical area of the tooth. Of these three are males, VEY-A-006 (25-35), 6 teeth, VEY-A-029 (35-45), 7 teeth and VEY-A-031 (unknown age), 1 tooth. One is female, VEY-A-007 (45+), 2 teeth, and one is an adult of unknown age and sex, VEY-A-011, 2 teeth.

Six individuals have dental abscesses. In one instance the abscess is secondary to a large caries, VEY-A-031 (a adult male of unknown age), who has a 3mm healed

cloaca above the root of the left maxillary 1st molar. The other cases are most likely caused by the infection getting into the bone due to gingivitis caused by irritation of the gums by calculus formation. There are three other cases of healed abscesses, between 4-6mm in diameter; VEY-A-007 (female, 45+), VEY-A-017 (male, 35-45) and VEY-A-029 (male, 35-45); all affecting the maxilla. There are also four instances of active abscesses, all with cloacae 3mm in diameter; VEY-A-004 (male, 45+), affecting the mandible; VEY-A-029 (male, 35-45), affecting the maxilla, and VEY-A-021 (female, 35-45) has two active abscesses, one in the mandible and the other in the maxilla.

A total of 350 were recorded as having some calculus formation. The molars were most frequently affected, and the calculus formation was most commonly just flecks, 56.9%, 34% was medium calculus formation and 9.1% was heavy calculus formation. A total of 25 adults had calculus formation; the results are presented in table 10.

Skeleton	Sex	Age	Number of teeth affected	Skeleton	Sex	Age	Number of teeth affected
VEY-A-001	M	35-45	21	VEY-A-015	M	18-25	9
VEY-A-002	F	35-45	12	VEY-A-016	F	45+	13
VEY-A-002b	M	?adult	3	VEY-A-017	M	35-45	22
VEY-A-003	M	35-45	18	VEY-A-017a	F	?adult	1
VEY-A-004	F	45+	4	VEY-A-020	F	25-35	11
VEY-A-005	F	25-35	17	VEY-A-021	F	35-45	11
VEY-A-006	M	25-35	27	VEY-A-021b	M	45+	29
VEY-A-007	F	45+	15	VEY-A-026	M	35-45	2
VEY-A-011	?	?adult	6	VEY-A-027	M	35-45	14
VEY-A-012	M	35-45	30	VEY-A-028	M	35-45	9
VEY-A-013	M	35-45	29	VEY-A-029	M	35-45	19
VEY-A-014	F	35-45	4	VEY-A-031	M	?adult	21
VEY-A-014a	F	18-25	3				

Table 10. VEY calculus.

There is one case of an impacted tooth. Macroscopically, a growth could be seen penetrating the right maxilla of VEY-A-007 (female, 45+), superior to where the canine should have been (all the teeth between the right and left 1st premolars are absent ante mortem). An X-ray of the cranium showed this to be an impacted tooth, probably the canine.

- Periodontal disease 16.7%
- Ante-mortem tooth loss 41.7%
- Caries 17.2%

- *Abscesses 16.7%*
- *Calculus 69.4%*
- *Impacted tooth 2.8%*

6.2.11 OTHER

Some other changes have been recorded that have not yet been diagnosed, and will have to be X-rayed before that can be done. These are all on skeleton VEY-A-007 (female, 45+). First of all there is a small lytic lesion, 7mm in diameter, perforating the endocranial surface of the left parietal in the region of the parietal tuberosity. In addition there is long-standing lamellar bone on the medial pterygoid plates of the sphenoid, and bilateral focused lytic lesions, approximately 16mm in diameter superior to the medial malleolus on the medial surface of the tibiae. Whether these changes are all part of the same disease process is uncertain, but hopefully further clarification will be given with X-rays.

7 CONCLUSION

The results after the first stage of analysis for this project are extremely promising. Although there is some variation in the preservation of the material, its preservation in general is very good, so the collections are very well suited to palaeopathological analysis, as the results show.

The next stage of this project is to continue the analysis. A total of 138 skeletons are scheduled to be analysed in 2004. These are from the cemeteries in Auðbrekka in Skriðuhreppur, Bessastaðir in Álftanes, Hella in Árskógsströnd and Reykjavík, as well as 82 skeletons from pagan burials from all around the country.

Once the recording of the skeletal pathologies is complete, the second stage of the analysis will be carried out, with comparative studies between the sites. However, some initial and tentative comparisons can be made between the two larger sites that were recorded in 2003: the medieval site of Haffjarðarey (13th-16th century) and the early modern site of Viðey (18th-19th century). The status and occupation of the individuals buried in these two cemeteries is likely to have been very dissimilar. The individuals in the Haffjarðarey cemetery are probably the local farmers, labourers used to manual work, while those in the Viðey cemetery are likely to have been of a

higher status. This is probably reflected in the incidence of osteoarthritis at the two sites, which is in almost all instances higher in the skeletons from Haffjarðarey. Only osteoarthritis of the cervical vertebrae is higher in Viðey, while in Haffjarðarey, for example, 14.8% have osteoarthritis of the lumbar vertebrae, while only 2.8% in the Viðey collection suffer from the same, and 16.7% in the Haffjarðarey collection have ankle or foot osteoarthritis, compared to 8.3% in Viðey. On the other hand the incidence of infectious disease is higher in the Viðey collection, 33.3% as opposed to 24.2% in Haffjarðarey, probably a result of the individuals buried in Viðey living in a larger town population, in closer proximity to each other and with more movement of people in and out of the area, factors which increase the risk of spreading disease. The Viðey population also has a much higher incidence of caries, 17.2% compared to 3.7% in the Haffjarðarey population, reflecting mainly accessibility to sugar and other cariogenic substances, not only because of the higher status of those buried in the Viðey cemetery, but also due to the fact that it is of a later date. There is also a clear difference in stature in the two populations; the average height for men in Viðey was 170cm, but 177cm in Haffjarðarey. This tentatively supports Jón Steffensen's research, which indicated that stature of Icelanders started decreasing in the 16th century, and did not start to increase again until the 18th century (Jón Steffensen, 1958). There are other factors which merit attention within each population, for example the high incidence of high uric acid in the Viðey population, might suggest a genetic factor, in particular due to the young age of some of those affected, indicating a familial relationship between those buried there, and the high incidence of neck trauma or strangulation in the Haffjarðarey collection merits further study.

REFERENCES

- Aufderheide, A.C. & Rodriguez-Martin, C. 1998. *The Cambridge Encyclopaedia of Human Paleopathology*. (Cambridge University Press; Cambridge).
- Bass, W.M. 1995. *Human Osteology*. (Special Publication No.2 of the Missouri Archaeological Society).
- Brooks, S.T. & Suchey, J.M. 1990. Skeletal Age Determination Based on the Os Pubis: A comparison of the Aszádi-Nemeséri and Suchey-Brooks Methods. *Human Evolution*. **5**: 227-238.
- Brothwell, D.R. 1981. *Digging up Bones*. (Oxford University Press; Oxford).
- Buikstra, J.E. & Ubelaker D.H. 1994. *Standards for Data Collection from Human Skeletal Remains*. (Arkansas Archaeological Survey Research Series No.44).
- Hoppa, R.D. 1992. Evaluating Human Skeletal Growth: an Anglo-Saxon Example. *International Journal of Osteoarchaeology*. **2**: 275-288.
- JÁM V**: Jarðabók Árna Magnússonar & Páls Vídalín V. Hnappadals- og Snæfellssýsla. 1931-33. (S.L.Möller: Kaupmannahöfn).
- Jón Steffensen, 1945. Rannsóknir á kirkjugarðinum í Haffjarðarey sumarið 1945. *Skírnir*. **CXX**: 144-162.
- Jón Steffensen. 1958. Stature as a criterion of the Nutritional level og Viking age Icelanders. Kristján Eldjárn (ed.) *Third Viking Congress, Reykjavík Árbók Hins íslenska fornleifafélags 1958, fylgirit*. pp. 39-51.
- Jón Steffensen. 1975. Þjórsdælir hinir fornu. In Jón Steffensen (ed.) *Menning og meinsemdir*. (Ísafoldarprentsmiðja, Reykjavík).
- Lilja Árnadóttir, 1982. Fundin mannabein í Neðranesi. *Árbók Hins íslenska fornleifafélags*. **1981**: 48-50.
- Lovejoy, C.O., Meindl, R.S., Pryzbeck, T.R. & Mensforth, R.P. 1985. Chronological Metamorphosis of the Auricular Surface of the Ilium: A New Method for the Determination of Age of Death. *American Journal of Physical Anthropology* **68**: 15-28.
- Margrét Hallgrímsdóttir. 1989. *Viðey. Fornleifarannsóknir 1988-1989*. (Skýrslur Árbæjarsafns I).
- Margrét Hallgrímsdóttir. 1993. *Húsakostur Viðeyjarklausturs. Um byggð í Viðey fram á 18. öld*. (Skýrslur Árbæjarsafns XXIX).
- Meindl, R.S. & Lovejoy, C.O. 1985. Ectocranial Suture Closure Ageing Scheme. *American Journal of Physical Anthropology* **68**: 57-66.
- Miles, A.E.W. 1963. The Dentition in the Assessment of Individual Age in Skeletal Material, pp 191-209. Brothwell, D. (ed). *Dental Anthropology*. (Pergamon Press: Oxford).
- Ortner, D.J. 1996. *Classification of Bone Lesions*. (Draft document).
- Ortner, D.J. & Putschar, W.G.J. 1981. *Identification of Pathological Conditions in Human Skeletal Remains*. (Smithsonian Institution Press: Washington).
- Roberts, C & Manchester, K. 1995. *The Archaeology of Disease*. 2nd edition. (Cornell University Press; Ithica, NY).
- Scheur, J.L., Musgrave, J.H. & Evans, S.P. 1980. The Estimation of Late Fetal and Perinatal Bone Length by Linear and Logarithmic Regression. *Annals of Human Biology*. **7**: 257-265.
- Schwartz, J.H. 1995. *Skeleton Keys*. (Oxford University Press: Oxford).
- Steele, D.G. & McKern, T.W. 1969. A Method for Assessment of Maximum Bone length and Living Stature from Fragmentary Long Bones. *American Journal of Physical Anthropology* **31**: 215-228.

- Trotter, M. & Gleser, G.C. 1958. A Re-evaluation of Estimation of Stature Based on Measurements of Stature taken during Life and Long Limb Bones after Death. *American Journal of Physical Anthropology* **16**: 79-123.
- Ubelaker, D.H. 1989. *Skeletal Remains*. (Taraxacum Press: Washington DC).
- Velasquez-Smith, M.T., Mason, C., Coonar, H. & Bennett, J. 1999. A nasopalatine cyst in an 8-year-old child. *International Journal of Paediatric Dentistry*. **9**: 123-127.

APPENDIX A – HAFFJARDAREY

Skeleton	Preservation	Sex	Age	Stature (cm)
HFE-A-001	75-90%	--	4-8	--
HFE-A-002	75-90%	--	8-13	--
HFE-A-003	75-90%	--	4-8	--
HFE-A-004	30-50%	?	?adult	163±2
HFE-A-005	50-75%	--	4-8	--
HFE-A-006	50-75%	Female	18-25	159,4±1,7
HFE-A-007	75-90%	Female	18-25	160,1±2,7
HFE-A-008	75-90%	Female	35-45	161,0±2,8
HFE-A-009	50-75%	--	4-8	--
HFE-A-010	>90%	--	8-13	--
HFE-A-011	>90%	Male	35-45	179,2±1,5
HFE-A-012	>90%	--	0-0.5	--
HFE-A-013	50-75%	Female	35-45	154,8±1,5
HFE-A-014a	30-50%	--	-36wks	--
HFE-A-014aa	50-75%	--	0-0.5	--
HFE-A-014b	50-75%	--	0.5-1	--
HFE-A-014d	50-75%	--	36-40wks	--
HFE-A-014e	75-90%	Male	35-45	?
HFE-A-014f	75-90%	Female	25-35	177,6±2,3
HFE-A-014g	75-90%	Female	25-35	168,2±2,3
HFE-A-014h	50-75%	Female	35-45	156,6±3,9
HFE-A-014i	50-75%	--	8-13	157,1±2,1
HFE-A-014j	50-75%	--	1-4	--
HFE-A-014k	50-75%	--	0.5-1	--
HFE-A-014l	30-50%	--	1-4	--
HFE-A-014m	30-50%	--	4-8	--
HFE-A-014n	30-50%	--	8-13	--
HFE-A-015	75-90%	Female	45+	?
HFE-A-016	75-90%	Female	25-35	151,3±1,7
HFE-A-017a	>90%	--	4-8	162,1±4,1
HFE-A-017b	50-75%	--	1-4	--
HFE-A-017c	50-75%	--	36-40wks	--
HFE-A-018	>90%	Male	35-45	?
HFE-A-019	>90%	Male	25-35	173,3±2,0
HFE-A-020	75-90%	Female	35-45	180,0±2,0
HFE-A-021a	>90%	--	8-13	162,2±2,0
HFE-A-021b	>90%	--	8-13	--

Skeleton	Preservation	Sex	Age	Stature (cm)
HFE-A-022	75-90%	Male	35-45	?
HFE-A-023	30-50%	?	?adult	174,5±2,6
HFE-A-024	30-50%	Female	18-25	?
HFE-A-025	30-50%	Male	35-45	?
HFE-A-026	30-50%	--	8-13	--
HFE-A-027	50-75%	--	8-13	--
HFE-A-028	50-75%	--	8-13	--
HFE-A-029	50-75%	--	1-4	--
HFE-A-030	50-75%	--	1-4	--
HFE-A-031	30-50%	--	0-0.5	--
HFE-A-032	30-50%	Female	18-25	?
HFE-A-033	30-50%	Male	45+	148,8±1,5
HFE-A-034	30-50%	Female	35-45	?
HFE-A-035	<30%	--	-36wks	--

APPENDIX B – HFE-A-014C

Bone	Side	Segment	Condition	MNI ¹	Count	Age	Sex	Comment
Frontal	R	N/A	Complete		1	<1	?juv	These two bones are part of the same individual
Frontal	L	N/A	Broken and glued	1	1	<1	?juv	
Temporal	R	N/A	Complete	1	1	0-0.5	?juv	
Occipital	N/A	N/A	Complete	1	1	0-0.5	?juv	
Mandible	N/A	N/A	Left side broken PM		1	1-1,5	?juv	
Mandible	R	N/A	Complete		1	0-0.5	?juv	These two bones are not part of the same individual
Mandible	L	N/A	Complete	3	1	0-0.5	?juv	
Clavicle	L	N/A	Complete	1	1	0-0.5	?juv	
Scapula	R	N/A	Complete		1	0-0.5	?juv	These two bones are not part of the same individual
Scapula	L	N/A	Complete	2	1	0-0.5	?juv	
Humerus	R	N/A	Complete	1	1	0-0.5	?juv	77mm. Periostitis, same individual as R tibia?
Radius	R	N/A	Complete		1	0-0.5	?juv	58mm
Radius	L	N/A	Complete	2	1	Foetus	?juv	51mm
Ulna	L	N/A	Complete	1	1	0-0.5	?juv	64mm
Os coxa	R	Ilium	Some damage to blade PM	1	1	0-0.5	?juv	
Tibia	R	N/A	1 complete, 2 distal third absent PM		3	0-0.5	?juv	The whole one is 84mm, the other two are much smaller. One of the broken ones has periostitis, same individual as humerus?
Tibia	L	N/A	Complete	3	2	Foetus	?juv	
Total				3	20			

¹ Minimum number of individuals

APPENDIX C - NEĐRANES

Skeleton	Preservation	Sex	Age	Stature (cm)
NNS-A-001	50-75%	--	8-13	--
NNS-A-002	50-75%	Female?	35-45	167
NNS-A-003	50-75%	--	1-4	--
NNS-A-004	30-50%	--	4-8	--
NNS-A-005	50-75%	Male	35-45	163.5
NNS-A-006	30-50%	Female?	35-45	155
NNS-A-007	30-50%	Female	?adult	160.3±4.9
NNS-A-008	<3*%	?	?adult	?

APPENDIX D – VIDEY

Skeleton	Preservation	Sex	Age	Stature (cm)
VEY-A-001	>90%	Male	35-45	177,7±2,6
VEY-A-002	50-75%	Female	35-45	154.5±0.7
VEY-A-002a	>90%	--	0-0.5	--
VEY-A-002b	<30%	Male?	?adult	?
VEY-A-003	>90%	Male	35-45	171.5±2.3
VEY-A-004	75-90%	Female	45+	154.1±2.5
VEY-A-005	>90%	Female?	25-35	154.1±2.3
VEY-A-006	>90%	Male	25-35	171.2±3.8
VEY-A-007	75-90%	Female	45+	155.7±2.5
VEY-A-008	<30%	?	?adult	?
VEY-A-009	<30%	?	?adult	?
VEY-A-010	<30%	?	?	?
VEY-A-011	<30%	?	?adult	?
VEY-A-012	75-90%	Male	35-45	169.7±1.2
VEY-A-013	30-50%	Male	35-45	?
VEY-A-014	50-75%	Female	35-45	157.9±0.6
VEY-A-014a	<30%	Female?	18-24	?
VEY-A-015	>90%	Male	18-25	176.7±3,2
VEY-A-015a	<30%	?	?adult	?
VEY-A-016	30-50%	Female	45+	?
VEY-A-017	30-50%	Male	35-45	161.4±5.1
VEY-A-017a	30-50%	Female?	?adult	159.9±5.3
VEY-A-018	<30%	?	?adult	?
VEY-A-020	>90%	Female	25-35	151.1±3.1
VEY-A-021	>90%	Female	35-45	150.7±1.0
VEY-A-021b	75-90%	Male	45+	170.7±2.4
VEY-A-023	30-50%	--	13-18	--
VEY-A-026	>90%	Male	35-45	163.8±4.5
VEY-A-026a	<30%	Male?	?adult	?
VEY-A-027	30-50%	Male	35-45	?
VEY-A-028	50-75%	Male	35-45	165
VEY-A-029	75-90%	Male	35-45	173.1±1.3
VEY-A-030	30-50%	Male?	?adult	163.4±4.2
VEY-A-031	30-50%	Male	?adult	?
VEY-A-032a	<30%	Male?	?adult	?
VEY-A-032b	<30%	?	?adult	?
VEY-A-032c	<30%	Female	?adult	?